

# **Prediction of improvement of cerebral perfusion with I-123 iomazenil SPECT**

**Tatsuro TSUCHIDA, Yoshiharu YONEKURA, Norihiro SADATO, Norio TAKAHASHI,  
Kazutaka YAMAMOTO and Yasushi ISHII**

**Reprint from Annals of Nuclear Medicine Vol. 13 No. 4  
August 1999**

## Prediction of improvement of cerebral perfusion with I-123 iomazenil SPECT

Tatsuro TSUCHIDA,\* Yoshiharu YONEKURA,\*\* Norihiro SADATO,\*\* Norio TAKAHASHI,\* Kazutaka YAMAMOTO\* and Yasushi ISHII\*

*\*Department of Radiology and \*\*Biomedical Imaging Research Center,  
Fukui Medical University*

We report a case of 61-year old man who was suffering from cerebrovascular disease with right hemiparesis and received I-123 iomazenil (IMZ) SPECT prior to carotid endoarterectomy. Severe stenosis of the right internal carotid artery and occlusion of the left middle cerebral artery (MCA) were revealed by cerebral angiography, and a hypoperfused area in left MCA territory and crossed cerebellar diaschisis (CCD) on I-123 IMP SPECT was demonstrated. In contrast, IMZ SPECT showed symmetric normal distribution. After the carotid endoarterectomy, the hypoperfused area in left MCA territory on IMP SPECT and hemiparesis had improved. It is thought that IMZ SPECT can be a useful tool for the prediction of improvement of cerebral perfusion and the clinical outcome.

**Key words:** I-123 iomazenil, cerebrovascular disease, SPECT

### INTRODUCTION

IODINE-123 IOMAZENIL (IMZ) is known as a high-affinity radioligand used for the measurement of central benzodiazepine (BZD) receptors with SPECT.<sup>1</sup> Its usefulness in cerebrovascular diseases has been reported experimentally<sup>2,3</sup> and clinically,<sup>4–8</sup> but none of them were compared to the cerebral perfusion images before and after surgery. If change is predicted, IMZ SPECT can provide useful information on the clinical situation. We report a case of cerebrovascular disease in which IMZ SPECT was performed before carotid endoarterectomy and the clinical outcome was followed up.

### CASE REPORT

A 61-year-old man suffered from right hemiparesis while he was at work in his office. He was transferred to our hospital by ambulance. He was slightly drowsy and motor aphasia was recognized.

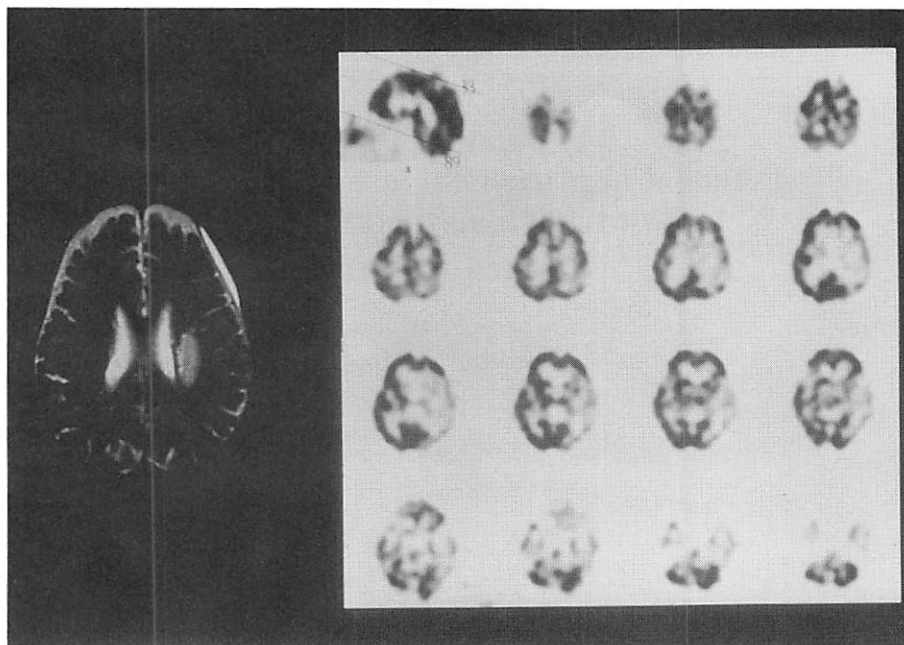
On MRI 8 days after the onset, a high intensity area in left white matter was observed in T2 weighted images and diagnosed as a white matter infarction (Fig. 1, left). Then for the assessment of cerebral perfusion, I-123 N-isopropyl-4-iodoamphetamine (IMP) SPECT was performed. Fifteen minutes postinjection of 111 MBq of IMP, SPECT images were obtained and hypoperfused areas in left middle cerebral artery (MCA) territory and crossed cerebellar diaschisis (CCD) were observed (Fig. 1, right). Eleven days after the IMP SPECT, I-123 iomazenil (IMZ) SPECT was performed. SPECT images were obtained 3 hours postinjection of 167 MBq of I-123 IMZ. In contrast to the IMP SPECT, no apparent reduced uptake area of IMZ was demonstrated (Fig. 2). Cerebral angiography was performed two days after the IMZ SPECT, and it demonstrated severe stenosis of the right internal carotid artery (ICA) and occlusion of the left MCA. From the MRI findings and angiography, this case was thought to be hemodynamic cerebral ischemia.

The patient received right carotid endoarterectomy (CEA) and the stenotic lesion was removed. Both motor aphasia and right hemiparesis were improved after the surgery. One month after the surgery, IMP SPECT was performed to examine the status of the cerebral perfusion. Although a slight hypoperfused area in left MCA territory was observed, the degree of hypoperfusion was

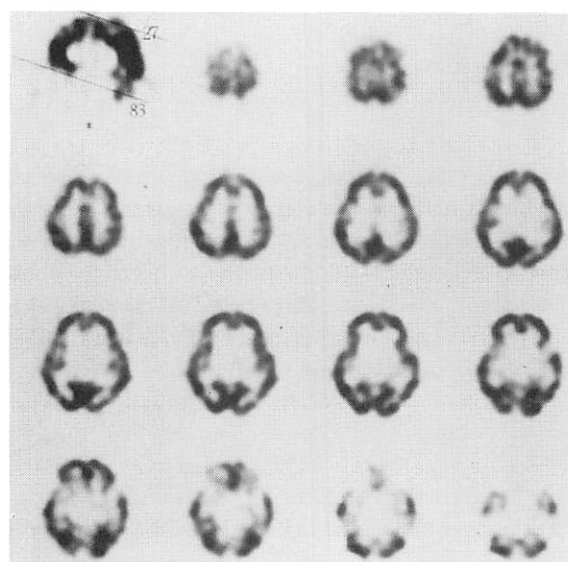
Received January 18, 1999, revision accepted March 3, 1999.

For reprint contact: Norio Takahashi, M.D., Department of Radiology, Fukui Medical University, 23 Shimoaizuki, Matsuoka-cho, Yoshida-gun, Fukui 910–1193, JAPAN.

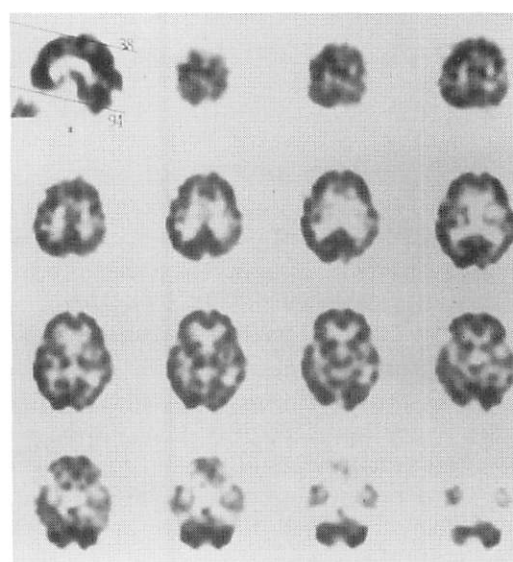
E-mail: noriot@fmsrsa.fukui-med.ac.jp



**Fig. 1** (left) T2-weighted MRI image. High intensity area which indicates infarction was observed in left white matter. (right) I-123 IMP SPECT images before surgery. Hypoperfused area in left middle cerebral artery (MCA) territory and crossed cerebellar diaschisis (CCD) were observed.



**Fig. 2** I-123 iomazenil (IMZ) images before surgery. No apparent reduced uptake area was demonstrated.



**Fig. 3** I-123 IMP SPECT images after surgery. Compared to IMP images before surgery, hypoperfused area in left MCA territory was significantly improved and CCD had disappeared.

apparently improved and CCD had disappeared after the surgical procedure (Fig. 3). On cerebral angiography after surgery, except for the removal of right ICA stenosis no remarkable change was observed.

All SPECT data were acquired with a triple-head rotating gamma camera (GCA 9300 A/HG, Toshiba, Tokyo) and the acquisition time was 20 minutes in each study. Parameters for reconstruction were as follows: pre-filter, Butterworth filter (filtered backprojection method); cut-

off frequency, 0.1; order, 8; reconstruction filter, ramp filter.

## DISCUSSION

The central BZD receptor is a postsynaptic membrane receptor ionophore complex which contains a gamma amino butyric acid (GABA) receptor.<sup>9</sup> IMZ binds to the

complex with higher affinity than carbon-11 flumazenil, the positron-emitting tracer for the measurement of BZD receptor.

For the measurement of BZD density, the mid-scan time of IMZ SPECT was set to 3 hours postinjection. Onishi et al.<sup>10</sup> reported that the binding potential images of IMZ obtained from compartmental analysis were very similar to the SPECT images acquired 3 hours postinjection of IMZ. We therefore thought that this image represented the BZD density and could predict the neuronal viability.

In cerebrovascular diseases, the behavior of IMZ in each stage of ischemic insult was reported in some literature. In experimental studies, Odano et al.<sup>2</sup> reported that in MCA-occluded gerbils the uptake of IMZ in the infarcted area was lower than that of deoxyglucose (DG) but in remote areas, such as thalamus and geniculate body, IMZ uptake was higher than DG uptake. It was confirmed histopathologically that there was mild neuronal degeneration in these areas, but some neurons remained intact. This indicates that IMZ can provide accurate representation of the actual viability of neurons in chronic cerebral infarction. Toyama et al.<sup>3</sup> also reported that the uptake of IMZ in peri-infarcted areas corresponded closely to the neuron distribution in rat 3 to 4 week after left MCA + common carotid artery (CCA) occlusion. In this period, the uptake of IMP was lower than that of IMZ. He indicated that the discrepancy might be useful in evaluating the neuronal damage.

In clinical studies, Hatazawa<sup>4</sup> and Sasaki et al.<sup>8</sup> reported that in the infarcted area and peri-infarcted area IMZ uptake was decreased corresponding to the decrease in cerebral blood flow. In contrast, in remote areas IMZ uptake was preserved. These results are caused by the difference in BZD density in each area. Changes in BZD binding are more sensitive to ischemic damage, and the preservation of the BZR binding after ischemia is predictive of the survival of brain tissue.<sup>11,12</sup>

With respect to IMZ uptake in misery perfusion areas, although Sasaki et al.<sup>8</sup> reported that IMZ uptake was preserved in misery perfusion areas, Hayashida et al.<sup>5</sup> reported different results. They divided 84 cortical areas of 7 patients into 4 groups according to their institutional criteria which depended on the severity of the hemodynamic and/or metabolic impairment. In the most severely impaired group (misery perfusion), IMZ uptake was correlated with the cerebral metabolic rate for oxygen (CMRO<sub>2</sub>). The difference between the results in the two papers<sup>5,8</sup> seemed to be due to the number and severity of misery perfusion they applied to their study. Two misery perfusion areas Sasaki et al. used had a normal CMRO<sub>2</sub> value. On the other hand, these areas which Hayashida et al. applied to their study had a sufficient number (n = 18) and variety for the estimation of regression analysis. Their data included the area which demonstrated normal CMRO<sub>2</sub>, and these limited areas were thought to be discussed in the paper by Sasaki et al.

In misery perfusion, the oxygen supply is not sufficient for the demand due to decreased cerebral blood flow (CBF), and a compensatory increase in the oxygen extraction fraction (OEF) occurs. If the decrease in CBF is moderate, CMRO<sub>2</sub> may be maintained by increased OEF. Once the reserve of oxygen is exhausted, any further transient drop in perfusion pressure would result in a decrease in CMRO<sub>2</sub>.<sup>13</sup> It is reported that regional measurement of CMRO<sub>2</sub> with PET accurately distinguishes viable from nonviable cerebral tissue and may be useful in the prospective identification of patients with reversible ischemia.<sup>14</sup> But PET has a disadvantage in that it cannot be made widely available; so that this information obtained from IMZ SPECT may be valuable in deciding on therapeutic approaches and IMZ SPECT may be able to take the place of PET.

In this case, the infarcted area was limited to the white matter region and no morphological change in the cerebral cortex observed on MRI and IMZ SPECT demonstrated preserved uptake in the cerebral cortex. In contrast, IMP SPECT revealed hypoperfusion in left MCA territory. From the MRI and SPECT findings, left MCA territory was thought to be an area of misery perfusion or diaschisis. As we had no information about oxygen metabolism in this area, we could not distinguish between these two conditions. Misery perfusion is known to be a good indication for surgery.<sup>15</sup> Meyer et al.<sup>16</sup> reported that the recovery of function was associated with the recovery of local perfusion and metabolism. Moreover, it is reported that in areas affected by transient ischemia or in areas remote from the infarct, selective neuronal damage occurs only in the neurons that are vulnerable to ischemia.<sup>17-19</sup> Therefore, surgery was thought to be effective for the improvement of cerebral perfusion and function, and in such a case as this, an operation might be acceptable even if misery perfusion and diaschisis could not be distinguished.

After surgery, we were able to confirm improvement in cerebral perfusion in left MCA territory where IMZ uptake was preserved and clinical symptoms. This mechanism was speculated to be as follows. Cerebral perfusion pressure in left MCA territory was regulated by not only the blood flow from left ICA but also right ICA via the circle of Willis. After CEA, the blood flow from right ICA was improved. As a result, cerebral perfusion pressure in left MCA territory increased and cerebral blood flow in that area was improved, and improvement in function was also brought as Meyer et al. reported.

In conclusion, IMZ SPECT was thought to provide useful information on the improvement in cerebral perfusion and the clinical outcome before surgery.

## ACKNOWLEDGMENTS

We thank Nihon Medi-Physics Co., Ltd. (Nishinomiya, Japan), for providing I-123 IMZ.

## REFERENCES

1. Beer HF, Bläuenstein PA, Hasler PH, Delaloye B, Riccabona G, Bangerl I, et al. *In vitro* and *in vivo* evaluation of iodine-123-Ro 16-0154: a new imaging agent for SPECT investigations of benzodiazepine receptors. *J Nucl Med* 31: 1007–1014, 1990.
2. Odano I, Miyashita K, Minoshima S, Nakajima T, Fujita M, Takahashi N, et al. A potential use of a  $^{123}\text{I}$ -labeled benzodiazepine receptor antagonist as a predictor of neuronal cell viability: comparisons with  $^{14}\text{C}$ -labeled 2-deoxyglucose autoradiography and histopathological examination. *Nucl Med Commun* 16: 443–446, 1995.
3. Toyama H, Matsumura K, Nakashima H, Takeda K, Takeuchi A, Koga S, et al. Characterization of neuronal damage by iomazenil binding and cerebral blood flow in an ischemic rat model. *Ann Nucl Med* 12: 267–273, 1998.
4. Hatazawa J, Satoh T, Shimosegawa E, Okudera T, Inugami A, Ogawa T, et al. Evaluation of cerebral infarction with iodine-123-Iomazenil SPECT. *J Nucl Med* 36: 2154–2161, 1995.
5. Hayashida K, Hirose Y, Tanaka Y, Miyashita K, Ishida Y, Miyake Y, et al. Reduction of  $^{123}\text{I}$ -iomazenil uptake in hemodynamically and metabolically impaired brain areas in patients with cerebrovascular disease. *Nucl Med Commun* 17: 701–705, 1996.
6. Nakagawara J, Sperling B, Lassen NA. Incomplete brain infarction of reperfused cortex may be quantitated with Iomazenil. *Stroke* 28: 124–132, 1997.
7. Dong Y, Fukuyama H, Nabatame H, Yamauchi H, Shibasaki H, Yonekura Y. Assessment of benzodiazepine receptors using iodine-123-labeled Iomazenil single-photon emission computed tomography in patients with ischemic cerebrovascular disease: a comparison with PET study. *Stroke* 28: 1776–1782, 1997.
8. Sasaki M, Ichiya Y, Kuwabara Y, Yoshida T, Fukumura T, Masuda K. Benzodiazepine receptors in chronic cerebrovascular disease: comparison with blood flow and metabolism. *J Nucl Med* 38: 1693–1698, 1997.
9. Olsen RW. The GABA postsynaptic membrane receptor-ionophore complex. *Moll Cell Biochem* 39: 261–279, 1981.
10. Onishi Y, Yonekura Y, Mukai T, Nishizawa S, Tanaka F, Okazawa H, et al. Simple quantification of benzodiazepine receptor binding and ligand transport using iodine-123-Iomazenil and two SPECT scans. *J Nucl Med* 36: 1201–1210, 1995.
11. Sette G, Baron JC, Young AR, Miyazawa H, Tillet I, Barre L, et al. *In vivo* mapping of brain benzodiazepine receptor changes by positron emission tomography after focal ischemia in the anesthetized baboon. *Stroke* 24: 2046–2058, 1993.
12. Onodera H, Sato G, Kogure K. GABA and benzodiazepine receptors in the gerbil brain after transient ischemia: demonstration by quantitative receptor autoradiography. *J Cereb Blood Flow Metab* 7: 82–88, 1987.
13. Leblanc R. Physiologic studies of cerebral ischemia. *Clin Neurosurg* 37: 289–311, 1991.
14. Powers WJ, Grubb RL Jr, Darriet D, Raichle ME. Cerebral blood flow and cerebral metabolic rate of oxygen requirements for cerebral function and viability in humans. *J Cereb Blood Flow Metab* 5: 600–608, 1985.
15. Muraishi K, Kameyama M, Sato K, Sirane R, Ogawa A, Yoshimoto T, et al. Cerebral circulatory and metabolic changes following EC/IC bypass surgery in cerebral occlusive diseases. *Neurol Res* 15: 97–103, 1993.
16. Meyer JS, Obara K, Muramatsu K. Diaschisis. *Neurol Res* 15: 362–366, 1993.
17. Graham DI. Hypoxia and vascular disorders. In: Adams JH, Duchon LW, eds., *Greenfield's Neuropathology*. London, England: Edward Arnold, pp. 153–268, 1992.
18. Kogure K, Kato H. Neurochemistry of stroke. In: Barnett HMJ, Mohr JP, Stain BM, Yatsu FM, eds., *Stroke: Pathophysiology, Diagnosis, and Management*. New York, NY: Churchill Livingstone, Inc., pp. 69–95, 1992.
19. Kirino T. Delayed neuronal death in the gerbil hippocampus following ischemia. *Brain Res* 239: 57–69, 1982.