

Intracerebral pain processing in a Yoga Master who claims not to feel pain during meditation

Ryusuke Kakigi^{a,b,d,*}, Hiroki Nakata^{a,b}, Koji Inui^{a,b}, Nobuo Hiroe^{a,b}, Osamu Nagata^a,
Manabu Honda^{b,c}, Satoshi Tanaka^{b,c}, Norihiro Sadato^{b,c,d}, Mitsumasa Kawakami^e

^a Department of Integrative Physiology, National Institute for Physiological Sciences, Nishigo-Naka 38, Myodaiji, Okazaki 444-8585, Japan

^b Department of Physiological Sciences, School of Life Sciences, The Graduate University for Advanced Studies, Hayama, Kanagawa, Japan

^c Department of Cerebral Research, Section of Cerebral Integration, National Institute for Physiological Sciences, Nishigo-Naka 38, Myodaiji, Okazaki 444-8585, Japan

^d Japan Science and Technology Agency, Kawaguchi, Japan

^e The Japan School of Yoga Meditation (Ashram), The ACC Research Center of Subconscious Psychology, Fukuoka and Tokyo, Japan

Received 3 March 2004; accepted 10 December 2004

Available online 20 January 2005

Abstract

We recorded magnetoencephalography (MEG) and functional magnetic resonance imaging (fMRI) following noxious laser stimulation in a Yoga Master who claims not to feel pain when meditating. As for background MEG activity, the power of alpha frequency bands peaking at around 10 Hz was much increased during meditation over occipital, parietal and temporal regions, when compared with the non-meditative state, which might mean the subject was very relaxed, though he did not fall asleep, during meditation. Primary pain-related cortical activities recorded from primary (SI) and secondary somatosensory cortices (SII) by MEG were very weak or absent during meditation. As for fMRI recording, there were remarkable changes in levels of activity in the thalamus, SII-insula (mainly the insula) and cingulate cortex between meditation and non-meditation. Activities in all three regions were increased during non-meditation, similar to results in normal subjects. In contrast, activities in all three regions were weaker during meditation, and the level was lower than the baseline in the thalamus. Recent neuroimaging and electrophysiological studies have clarified that the emotional aspect of pain perception mainly involves the insula and cingulate cortex. Though we cannot clearly explain this unusual condition in the Yoga Master, a change of multiple regions relating to pain perception could be responsible, since pain is a complex sensory and emotional experience.

© 2004 European Federation of Chapters of the International Association for the Study of Pain. Published by Elsevier Ltd. All rights reserved.

Keywords: Yoga; MEG; fMRI; Pain; Meditation

1. Introduction

It is claimed that with extensive training in the techniques of Yoga, feelings of pain can be blocked out during meditation, and some Yoga Masters have attempted

to demonstrate this by sticking needles into their tongue and cheek while in a meditative state. Pain processing in humans has been investigated (see Treede et al., 1999, 2000) using neuroimaging methods such as positron emission tomography (PET) (Talbot et al., 1991; Jones et al., 1991; Casey et al., 1994; Craig et al., 1996; Rainville et al., 1997, 1999, 2002; Xu et al., 1997; Svensson et al., 1997; Bushnell et al., 1999; Peyron et al., 2002), functional magnetic resonance imaging (fMRI) (Davis

* Corresponding author. Tel.: +81 564 55 7815; fax: +81 564 52 7913.

E-mail address: kakigi@nips.ac.jp (R. Kakigi).

et al., 1998, 2002; Sawamoto et al., 2000; Bantick et al., 2002; Coghill et al., 2003), and MEG (Huttunen et al., 1986; Kakigi et al., 1995; Hari et al., 1997; Watanabe et al., 1998; Yamasaki et al., 1999; Ploner et al., 1999; Kanda et al., 1999; Inui et al., 2003; Nakata et al., 2004). MEG is used to analyze background brain activity and primary cortical evoked responses generated in mainly the SI and SII within a few hundred ms following stimulation due to its high temporal resolution. Therefore, one can evaluate the temporal dynamics of cortical processing in the order of ms with MEG, but one cannot evaluate brain rhythms or obtain detailed temporal information on cortical activities using fMRI. In contrast, event-related fMRI can record blood flow changes for at least 10 s following stimulation, and is useful for evaluating long-term processing of pain. In addition, fMRI can clearly detect activities located at depth such as in the thalamus and cingulate cortex, which MEG cannot easily detect. Therefore, by combining MEG and fMRI, detailed temporal and spatial information can be obtained. We recently had an opportunity to record MEG and fMRI following painful laser stimulation in a Yoga Master who claims not to feel pain during meditation and made several very interesting findings. To our knowledge, this is the first report investigating pain processing in such a unique individual using MEG and fMRI.

2. Methods

This study was first approved by the Ethical Committee of National Institute for Physiological Sciences, Okazaki, Japan.

2.1. Subjects

The subject, a 65-year-old male, has been practicing yoga for 38 years. He received the title Yoga Samrat, indicating the highest level of proficiency, from the Indian Yoga Culture Federation in 1983. The San Francisco State University has been doing a cooperative study with him for several years, and found an increase of alpha EEG activity, a pronounced abdominal breathing pattern, and no significant change of heart rate or blood volume pulse during meditation (Arambula et al., 2001). One surprising claim is that he does not feel pain at all during meditation. To demonstrate this, he sticks needles into his tongue and cheek. For this experiment, he strongly concentrated on not feeling pain from a laser stimulation, which he had never received before. He continued to meditate for more than 15 min, during the recording of MEG and fMRI. Since we have recorded MEG following painful laser stimulation in more than 60 normal subjects (Kakigi et al., 1995; Watanabe et al., 1998; Yamasaki et al., 1999; Nakata et al., 2004),

and recorded PET and fMRI in more than 40 normal subjects (Xu et al., 1997; Sawamoto et al., 2000, our unpublished study), we used those data as a control.

2.2. Laser stimulation

For noxious stimulation, a Tm:YAG laser beam (Neurolaser, BAASEL Lasertechnik, Germany) was applied to the dorsum of the left hand or foot. The wavelength was 2000 nm, pulse duration was 1 ms, and spot diameter was 6 mm. Interstimulus intervals were randomly varied between 8 and 15 s, and the irradiated points were moved slightly for each stimulus to avoid tissue damage and habituation of the receptors. The mean intensity was 320 mJ in normal subjects who felt a sharp pin-prick like pain. Since the pain threshold in this individual was relatively high, we needed a higher intensity, ≈ 450 mJ. During meditation, the subject told us that he did not feel pain at all. We asked him to evaluate the subjective strength of the pain intensity from 0 (no pain) to 10 (intolerable pain). He gave a score of 8 during non-meditation and zero during meditation.

2.3. MEG recording

MEG was recorded with a helmet-shaped 306-channel detector array (Vectorview; ELEKTA Neuromag Yo., Helsinki), which comprises 102 identical triple sensor elements, in a magnetically shielded room, but the signals recorded from 204 gradiometers were used for source localization in this study. Each sensor element consists of two orthogonal planar gradiometers and one magnetometer coupled to a multi-SQUID (Superconducting Quantum Interference Device). We analyzed the background brain activity using a frequency analysis of MEG. The period of analysis was two minutes in the mid-period of the session (between 2 and 4 min from the beginning of the session) during non-meditation and meditation while the laser beam was applied to the dorsum of the left hand.

Laser evoked magnetic fields (LEFs) were recorded following laser stimulation applied to the dorsum of the left hand. Fifty signals were recorded with a band-pass of 0.1–100 Hz and digitized at 900 Hz, and signals with noise, blinks and eye movement were excluded from the analysis automatically. The analysis period was 500 ms, including 100 ms before the stimulation that used for the baseline.

2.4. fMRI acquisition and analysis

For brain functional imaging, a single laser stimulation was applied to the dorsum of the left foot, since the hand could not be stimulated due to technical problems. One imaging session contained 40 stimuli in total, and 300 volumes of gradient echo single-shot echo

planner imaging (EPI) were acquired with a time of repetition of 2 s, time of echo of 30 ms, flip angle of 80°, field of view of 192 mm, and matrix size of 64 × 64, in 32 transaxial slices 3 mm thick without a gap, using a 3.0-T Siemens Allegra scanner. Two imaging sessions were performed, one for the meditative state and one for the non-meditative state with an interval of a few minutes.

The first 5 volumes of each session were discarded because of unsteady magnetization. The remaining data were analyzed by statistical parametric mapping with SPM 99 (Wellcome Department of Cognitive Neurology, London, UK) on Matlab (Mathworks, Natick, MA). The EPI images were realigned to the first image of the first session, and spatially smoothed with an 8 mm full-width at half-maximum isotropic Gaussian kernel. Using a general linear model, a weighting coefficient was calculated for a regressor of the stimulus. Statistical inference was first evaluated in terms of change in activity in response to the laser stimulus during non-meditation and meditation compared to the baseline period (before the stimulus) of each session. The resulting set of voxel values constituted a statistical parametric map (SPM) of the t statistics (SPM{ t }). The threshold for SPM{ t } was set at $P < 0.001$ without correction for multiple comparisons. The resulting set of significant voxels was superimposed onto each high-resolution anatomical image. Time course data on the signals at the voxel with maximal significance in the thalamus, SII-insula, and cingulate cortex (see Section 3) in the non-meditative state were averaged across all the trials time-locked to the onset of each stimulus and plotted using the preceding two sample points as the baseline.

3. Results

3.1. Background brain activity

We recorded background brain activity using a frequency analysis of MEG during both meditation and non-meditation. The power of alpha wave activity peaking at around 10 Hz showed a marked increase during meditation when compared with that during non-meditation (Fig. 1). During the experiment, the subject did not show any MEG change indicating that he fell into a sleep. These findings indicated that the condition of the brain during meditation was definitely different from that in non-meditation, the subject probably being very relaxed during meditation even while receiving noxious laser stimulation, but remaining awake. These findings were compatible with a previous study using EEG (Arambula et al., 2001), though they were recorded without applying noxious stimulation.

Regarding LEFs, we first show common findings in normal subjects (see Nakata et al., 2004). Clear re-

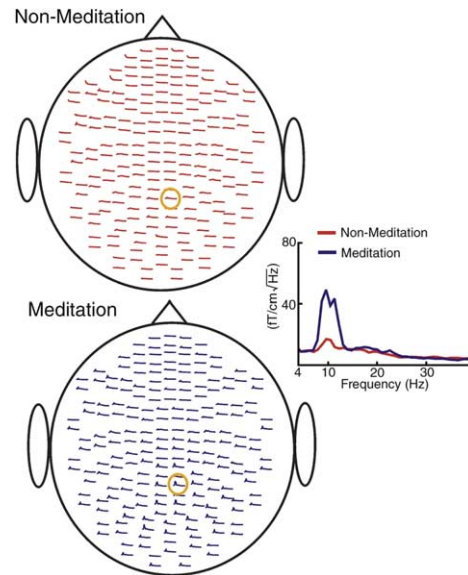


Fig. 1. Frequency analysis of background MEG activity of the Yoga Master over 2 min during non-meditation and meditation, while the laser stimulus was applied. The power of the alpha wave was much increased during meditation, indicating that the subject did not fall asleep.

sponses were recorded in three regions; SI contralateral to the stimulation and SII or SII-insula in bilateral hemispheres (Fig. 2). Peak latencies were between 170 and 200 ms following stimulation. Findings were generally compatible with previous studies (Ploner et al., 1999; Kanda et al., 1999). That is, the latency of the contralateral SI and SII showed no significant difference, indicating that the two sites were activated simultaneously. However, the peak latency of SII ipsilateral to the stimulation was significantly longer than that of the contralateral SI and SII, probably due to the time taken to pass through the corpus callosum.

Findings in the present study were as follows:

1. During non-meditation, the subject felt a painful pin-prick sensation, a score of 8 on a scale of 0–10, and the automatic flexion reflex was sometimes observed. LEFs showed questionable and unreliable low-amplitude SI and SII responses, which were much smaller than normal (Fig. 2).
2. During meditation, the subject claimed to feel no pain, a score of zero, or a light touch-like feeling. LEFs showed similar findings to those obtained during non-meditation (Fig. 2).

Since MEG showed questionable and unreliable low-amplitude responses during both non-meditation and meditation, we could not measure the peak latency and amplitude or conduct a source analysis for them.

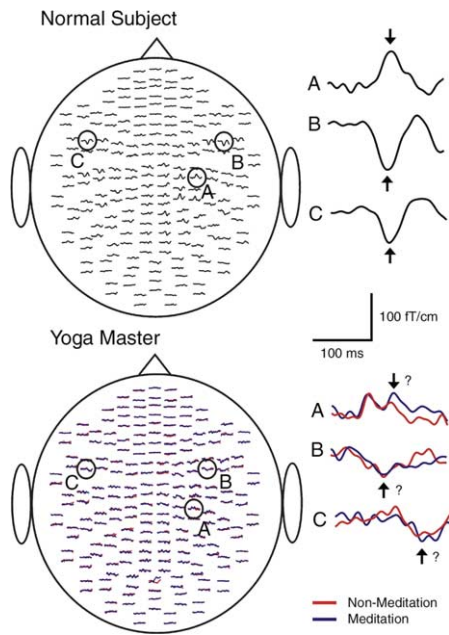


Fig. 2. Laser-evoked magnetic fields (LEFs) in a normal subject and the Yoga Master following noxious YAG laser stimulation applied to the dorsum of the left hand. The three regions shown by A, B and C were always activated in normal subjects. Enlarged waveforms recorded at A, B and C are shown on the right. Their dipoles were estimated to lie in the SI contralateral to, SII contralateral to, and SII ipsilateral to the site of stimulation for A, B and C, respectively. However, in the Yoga Master, they were questionable and unreliable with a low-amplitude during both non-meditation and meditation.

As for the fMRI study, we compared the regions of the brain with a significant increase of signal in response to the laser stimulus relative to the baseline period in each condition (Fig. 3 and Table 1). Many regions showed a significant increase in blood oxygen level dependent (BOLD) signals, and several regions such as some areas in the frontal gyrus showed a decrease of activities during meditation. However, the most remarkable difference between the non-meditative and meditative state was that there was little or no increase of BOLD signals in the following three regions, the thalamus (mainly the dorsomedial nucleus), SII-insula (mainly the insula) and cingulate cortex in meditative state. These three regions are often activated in PET and fMRI studies following painful laser stimulation (i.e., Xu et al., 1997; Svensson et al., 1997; Sawamoto et al., 2000) and are frequently focused on in human pain perception (Rainville et al., 1997; Hofbauer et al., 2001). Therefore, we focused on signal changes of these three regions between the non-meditative and meditative state. In addition, the superior frontal gyrus (BA8) in both hemispheres and the right superior parietal gyrus (BA7) were significantly activated during meditation compared with non-meditation. These regions may play some role in maintaining the meditative state. This finding is interesting but cannot be discussed in detail, since

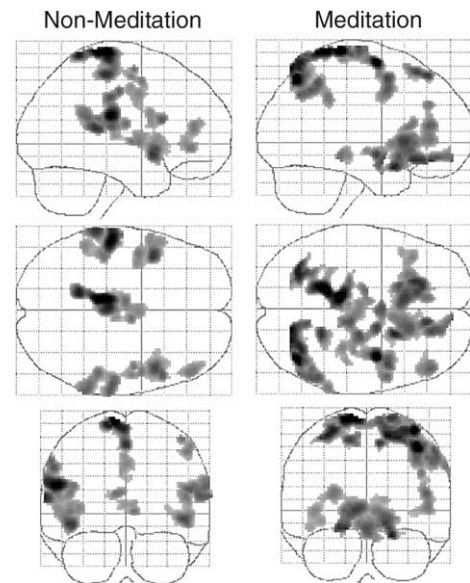


Fig. 3. Areas of the brain with transiently increased activity following laser stimulation during non-meditation (left) and meditation (right). Maps of t scores for the regions where activity was significantly increased from the baseline period during each state ($p < 0.05$ with a correction for multiple comparisons) are shown in a standard anatomical space (Talairach and Tournoux, 1988) viewed from the right side (upper), the top (middle), and the back (lower) of the brain. Maps are illustrated using a gray scale, with the lower t score represented in light gray and the higher ones in dark gray.

it is from one subject under specialized conditions while a painful laser beam is applied.

The findings in the three specific regions, the thalamus, SII-insula and cingulate cortex, can be summarized as follows:

1. During meditation, BOLD signals showed no significant increase of activity in any of the regions (Fig. 3(b)). The difference between meditation and non-meditation was significant in all the three regions (Figs. 4 and 5).
2. Time course data of the voxels showing the most significant increases in signal in each region during both meditation and non-meditation are shown in Fig. 6. The data were obtained from the voxel showing maximal significance of increased activity in each region. These voxels were defined based on the data obtained during non-meditation. The coordinates of these voxels are as follows: SII-insula [$x y z$] = $-56, -24, 22$; statistical t value = 9.09, thalamus [$x y z$] = $-8, -12, 16$; $t = 7.22$, and Cingulate cortex [$x y z$] = $2, -2, 40$; $t = 6.51$. During non-meditation, there was a gradual increase with a peak at 6 s after stimulation and then a gradual decrease in all three regions. By contrast, during meditation, there was a gradual decrease with a peak at 6 s after stimulation in the thalamus, though the change did not reach the signif-

Table 1

Regions of the brain with significantly increased signal relative to the baseline period during non-meditation and meditation

t-Value	Talairach coordinates			Brain regions
	x	y	z	
<i>During non-meditation</i>				
11.99	-10	-28	76	Foot region in the left SM1
10.76	-56	-24	22	Left SII-insula
8.83	-44	10	-8	Left anterior insula
8.35	46	12	-4	Right anterior insula
7.80	60	-24	14	Right SII-insula
7.68	50	16	20	Right inferior frontal gyrus (BA45)
7.22	-8	-12	16	Left thalamus
7.18	6	-8	2	Right thalamus
6.98	50	0	50	Right precentral gyrus
6.98	48	42	14	Right middle frontal gyrus (BA46)
6.51	2	-2	40	Cingulate cortex (BA24/32)
6.40	-54	6	26	Left inferior frontal gyrus (BA44)
<i>During meditation</i>				
11.71	-10	-34	74	Foot region in the left SM1
11.46	42	-68	50	Right superior parietal lobule (BA7)
8.80	20	-48	74	Right superior parietal lobule (BA7)
8.67	10	36	54	Right superior frontal gyrus (BA8)
8.41	-14	28	56	Left superior frontal gyrus (BA8)
7.55	48	38	14	Right middle frontal gyrus (BA46)
7.02	-6	-32	-10	Left tectum mesencephali
6.71	10	-32	-8	Right tectum mesencephali

Many regions are activated in both states, but a remarkable difference is the absence of activities in the thalamus, SII-insula, anterior insula and cingulate cortex and some areas in the frontal gyrus during meditation. By contrast, superior and inferior frontal gyri were activated only during meditation.

SM1: primary sensorimotor cortex.

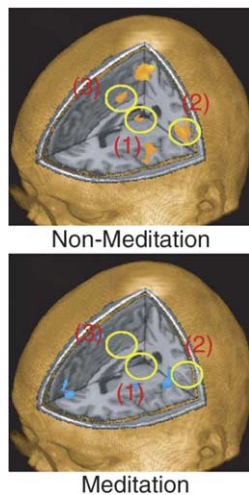


Fig. 4. fMRI findings during non-meditation and meditation in the Yoga Master following noxious YAG laser stimulation applied to the dorsum of the left foot. The thalamus (1), SII-insula (2) and cingulate cortex (3) were analyzed. During non-meditation, activities in all three regions were significantly increased, but during meditation, no activation was identified in any of the regions.

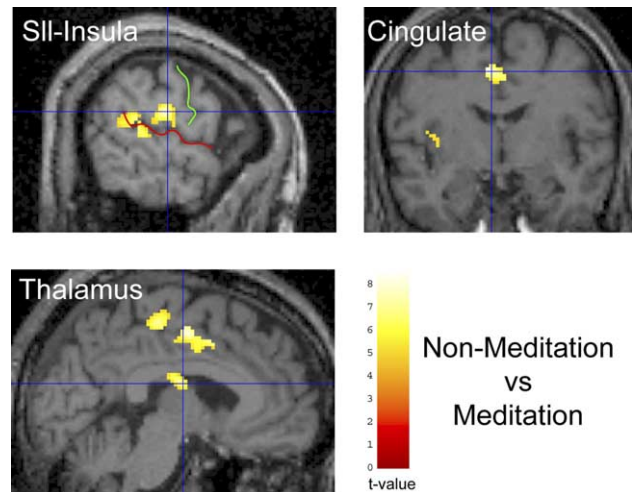


Fig. 5. The difference between the meditative state and non-meditative state was significant using the general linear model in all three regions, the thalamus, SII-insula and cingulate cortex. Central sulcus and Sylvian fissure are shown in the figure.

icant level. In contrast, there was a gradual increase with a peak at 6 s in the SII-insula and cingulate cortex, though the degree of this increase was approxi-

mately 20% (SII-insula) and 40% (cingulate cortex) of that for non-meditation, but it did not reach the predetermined statistical threshold.

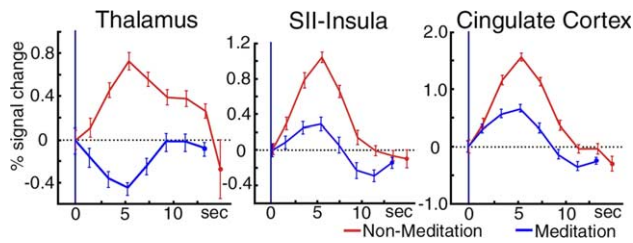


Fig. 6. Time course of activities in the thalamus, SII-insula and cingulate cortex during both non-meditation and meditation in the Yoga Master following noxious YAG laser stimulation applied to the dorsum of the left foot. Activities in all three regions were weaker during meditation, and the level was lower than the baseline in the thalamus. Error bars indicate the standard deviation of trials.

4. Discussion

Since this is the first study to analyze MEG and fMRI findings in an individual who claims not to feel pain while meditating, we cannot refer to previous findings. There have been EEG reports for subjects who had practiced yoga for several years, but their findings were not consistent, that is, increased alpha or theta EEG activity (Kasamatsu and Hirai, 1966; Kasamatsu et al., 1957; Herbert and Lehmann, 1977; Becker and Shapiro, 1981). There have been a few PET studies on subjects in a meditative state (Herzog et al., 1990–1991; Lou et al., 1999; Kjaer et al., 2002), but their findings were not consistent either. The inconsistency is probably due to a large inter-individual difference caused by how long and how intensely they practiced yoga. Actually, experts in yoga meditation such as the subject in this study are rarely available to researchers (Arambula et al., 2001). In addition, these previous studies did not include an individual who claimed not to feel pain while meditating and, of course, PET was recorded without applying pain.

The findings of LEF during non-meditation (questionable and unreliable SI and SII responses) were interesting but quite unexpected. Since fMRI activity was increased in the thalamus, SII-insula and cingulate cortex during non-meditation, ascending signals should reach the SI and SII. Though it is difficult or impossible to explain this particular phenomenon, we now have one hypothesis that the neuronal activities in the SI and SII for the early processing of pain (within 200 ms following stimulation) have gradually been attenuated by long-term training in Yoga, resulting in a kind of plasticity, and so the responses evoked by painful stimulation are smaller in amplitude causing a low signal-to-noise ratio, though this is mere speculation. Since we applied a stronger stimulus well above the pain threshold of this subject, the stimulus intensity could not be the main cause. The age of the subject, 65 years, also might explain the reduced neuronal activities, but no such marked reduction was identified in our previous experiences.

During meditation, the primary responses in the SI and SII recorded by LEFs were small. Activity levels in the SII-insula and cingulate cortex determined by fMRI were slightly increased, but did not reach the significant level during meditation. These findings were compatible with the subjective report of no pain at all during meditation. Interestingly and surprisingly, fMRI activity in the thalamus was decreased, peaking at 6 s, though the degree of change was not significant. There are three main possibilities for this particular finding. The first possibility is that inhibition took place below the thalamus and signals did not reach the thalamus. As for the effects of attentional tasks on nociceptive brain activity, Bushnell et al. (1984) demonstrated that magnitudes of thermal responses of trigeminothalamic neurons of monkeys were modulated by attentional state. Therefore, the decreased activity in the thalamus during meditation in the present study may be a result of the inhibitory action of meditation-induced brain activity on spinal nociceptive neurons. The spinal cord receives projections from various cortical regions relating to nociception, including the anterior cingulate cortex (Biber et al., 1978; Dum and Strick, 1991; He et al., 1995). The second possibility is that some particular event took place in the thalamus, which caused extensive inhibition of subsequent pain processing, so activities in the SI, SII-insula and cingulate cortex were very weak or absent.

We may have to consider a third possibility caused by a specific psychological endogenous mechanism, since it is well known that the degree of pain perception is much affected by attention/distraction. In particular, hypnosis should be considered. Recently, there have been several neuroimaging studies to elucidate the underlying mechanisms of hypnosis (Rainville et al., 1999; Hofbauer et al., 2001; Faymonville et al., 2003). Rainville et al. (1999) recorded background EEG activity and regional cerebral blood flow (rCBF) changes during hypnosis by PET. Their results supported a state theory of hypnosis, in which occipital increases in rCBF and delta EEG activity reflect the alteration of consciousness associated with decreased arousal and possible facilitation of visual imagery. Faymonville et al. (2003), using PET, found that the activity in the anterior cingulate cortex covaried with the hypnosis-induced reduction of affective and sensory responses to noxious thermal stimulation. They also reported that a hypnotic state, compared to normal alertness, significantly enhanced the functional modulation between the mid-cingulate cortex and a large neural network encompassing the bilateral insula, pregenual anterior cingulate cortex, pre-supplementary motor area, right prefrontal cortex, striatum, thalamus and brainstem, and suggested a critical role for the mid-cingulate cortex in the modulation of a large cortical and subcortical network underlying its influence on sensory, affective, cognitive and behavioral aspects of nocicep-

tion, in the specific context of hypnosis (Faymonville et al., 2003). Since the main change of background MEG (in the present study) and EEG activity (Arambula et al., 2001) during meditation in the Yoga Master was in the power of the alpha frequency bands which was much increased, the condition of the brain during meditation seems very different from that during hypnosis (Rainville et al., 1999). However, if the cingulate cortex played a critical role in the modulation of a cortical and subcortical network during both hypnosis and meditation, a decrease of activity in the SII-insula and thalamus might be caused by a change of activity in the cingulate cortex, that is, an endogenous change.

One has to consider the anatomical background to the network on pain perception to evaluate the present results. Signals evoked by noxious stimuli applied to the skin ascend through the spinothalamic tract to reach the thalamic nuclei, including the ventroposterior lateral (VPL), ventroposterior inferior (VPI) and mediodorsal (MD) nucleus. From the VPL and VPI nuclei, the information reaches the SI (Nelson and Kaas, 1981) and SII (Jones and Powell, 1970; Friedman and Murray, 1986), while the cingulate cortex receives its main inputs from the MD nucleus (Vogt et al., 1987). The insular cortex receives inputs from several thalamic nuclei including the VPI and basal ventromedial (VMb) nuclei (Friedman and Murray, 1986). In addition to the direct inputs from the thalamus, the SII and cingulate cortex receive dense afferents from the SI (Vogt and Pandya, 1978; Friedman et al., 1986) and insula (Mesulam and Mufson, 1982; Vogt and Pandya, 1987), respectively. In addition, to support our hypothesis, anatomical studies of animals have shown projections from the cingulate cortex to the insula (Pandya et al., 1981; Jasmin et al., 2004) and MD (Yeterian and Pandya, 1988). Recent studies have shown that the thalamic relay neurons receive substantial numbers of inputs from the cerebral cortex, and that feedback from the cortex plays a crucial role in shaping thalamic responses (for review, see Alitto and Usrey, 2003 or Jones, 2002). The insular cortex receives inputs from several thalamic nuclei including the VPI, basal ventromedial (VMb) (Friedman and Murray, 1986) and posterior part of the ventromedial (VMpo) nuclei (Craig et al., 1994), although the significance of the VMpo is still controversial (Willis et al., 2002; Graziano and Jones, 2004; Lenz et al., 2004; Craig, 2004).

Therefore, modulation of thalamic activity by behaviorally relevant tasks in previous studies may be a result of such feedback mechanisms. For example, O'Connor et al. (2002) demonstrated that attentional task demands could significantly modify lateral geniculate nucleus (LGN) activity in humans. Although less is known regarding such feedback mechanisms in nociceptive thalamic neurons, it seems reasonable to speculate that such mechanisms might cause this particular phenomenon in the Yoga Master.

In conclusion, the findings of this study strongly suggest that the subject, a Master of Yoga, really did not feel pain during meditation. We now hypothesize that extensive training in the techniques of Yoga meditation caused such an extreme psychological change. Changes in the thalamus may be the cause of this particular effect, but modulation below the thalamus or cerebral cortex, particularly, the cingulate cortex, may also change the activity of the thalamus. It is impossible to conclude what happens in the brain of the Yoga Master during meditation given that we still do not know why a change in mental state affects pain perception, but this is an interesting and important issue related to the underlying mechanisms for pain perception in humans.

Acknowledgements

We are very grateful to Dr. Sachiko Yamamoto, Dr. Daisuke Saito, Dr. Xiaohong Wang, Dr. Yunhai Qiu, and Yasuyuki Takeshima in our Institute and Hiroko Asano and Hirokazu Suzuki, TBS Vision, Tokyo, Japan, for technical help during this study.

References

- Alitto HJ, Usrey WM. Corticothalamic feedback and sensory processing. *Curr Opin Neurobiol* 2003;13:440–5.
- Arambula P, Pepper E, Kawakami M, Gibney KH. The physiological correlates of Kundalini Yoga meditation: a study of a Yoga master. *Appl Psychophysiol Biofeedback* 2001;26:147–53.
- Bantick SJ, Wise RG, Ploghaus A, Clare S, Smith SM, Tracey I. Imaging how attention modulates pain in humans using functional MRI. *Brain* 2002;125:310–9.
- Becker DE, Shapiro D. Physiological responses to clicks during zen, yoga, and TM meditation. *Psychophysiology* 1981;18:694–9.
- Biber MP, Kneisley LW, LaVail JH. Cortical neurons projecting to the cervical and lumbar enlargements of the spinal cord in young and adult rhesus monkeys. *Exp Neurol* 1978;59:492–508.
- Bushnell MC, Duncan GH, Dubner R, He LF. Activity of trigeminothalamic neurons in medullary dorsal horn of awake monkeys trained in a thermal discrimination task. *J Neurophysiol* 1984;52:170–87.
- Bushnell MC, Duncan GH, Hofbauer RK, Ha HB, Chen JL, Carrier B. Pain perception: is there a role for primary somatosensory cortex. *Proc Natl Acad Sci USA* 1999;96:7705–9.
- Casey KL, Minoshima S, Berger KL, Koeppe RA, Morrow TJ, Frey KA. Positron emission tomographic analysis of cerebral structures activated specifically by repetitive noxious heat stimuli. *J Neurophysiol* 1994;71:802–7.
- Coghill RC, McHaffie JG, Yen Y-F. Neural correlates of interindividual differences in the subjective experience of pain. *Proc Natl Acad Sci USA* 2003;100:8358–542.
- Craig AD. Distribution of trigeminothalamic and spinothalamic lamina I terminations in the macaque monkey. *J Comp Neurol* 2004;477:119–48.
- Craig AD, Bushnell MC, Zhang ET, Blomquist A. A thalamic nucleus specific for pain and temperature sensation. *Nature* 1994;372:770–3.

- Craig AD, Reiman EM, Evans A, Bushnell MC. Functional imaging of an illusion of pain. *Nature* 1996;384:258–60.
- Davis KD, Kwan CL, Crawley AP, Miklis DJ. Functional MRI study of thalamic and cortical activations evoked by cutaneous heat, cold, and tactile stimuli. *J Neurophysiol* 1998;80:1533–46.
- Davis KD, Pope GE, Crawley AP, Mikulis DJ. Neural correlates of prickle sensation: a percept-related fMRI study. *Nat Neurosci* 2002;5:1121–2.
- Dum RP, Strick PL. The origin of corticospinal projections from the premotor areas in the frontal lobe. *J Neurosci* 1991;11:667–89.
- Faymonville ME, Roediger L, Del Fiore G, Delgueldre C, Phillips C, Lamy M, et al. Increased cerebral functional connectivity underlying the antinociceptive effects of hypnosis. *Brain Res Cogn Brain Res* 2003;17:255–62.
- Friedman DP, Murray EA. Thalamic connectivity of the second somatosensory area and neighboring somatosensory fields of the lateral sulcus of the macaque. *J Comp Neurol* 1986;252:348–73.
- Friedman DP, Murray EA, O'Neill B, Mishkin M. Cortical connections of the somatosensory fields of the lateral sulcus of macaques: evidence for a corticolimbic pathway for touch. *J Comp Neurol* 1986;252:323–47.
- Graziano A, Jones EG. Widespread thalamic terminations of fibers arising in the superficial medullary dorsal horn of monkeys and their relation to calbindin immunoreactivity. *J Neurosci* 2004;24:248–56.
- Hari R, Portin K, Kettenmann B, Jousmäki V, Kopal G. Right-hemisphere predominance of responses to painful CO₂ stimulation of the human nasal mucosa. *Pain* 1997;72:145–51.
- He SQ, Dum RP, Strick PL. Topographic organization of corticospinal projections from the frontal lobe: motor areas on the medial surface of the hemisphere. *J Neurosci* 1995;15:3284–306.
- Herbert R, Lehmann D. Theta bursts: an EEG pattern in normal subjects practicing the transcendental meditation technique. *Electroencephalogr Clin Neurophysiol* 1977;42:397–405.
- Herzog H, Lele VR, Kuwert T, Langen KJ, Kops ER, Feinendegen LE. Changed pattern of regional glucose metabolism during yoga meditative relaxation. *Neuropsychobiology* 1990–1991;23:182–7.
- Hofbauer RK, Rainville P, Duncan GH, Bushnell MC. Cortical representation of the sensory dimension of pain. *J Neurophysiol* 2001;86:402–11.
- Huttunen J, Kopal G, Kaukoranta E, Hari R. Cortical responses to painful CO₂ stimulation of nasal mucosa; a magnetoencephalographic study in man. *Electroencephalogr Clin Neurophysiol* 1986;64:347–9.
- Inui K, Tran TD, Qiu Y, Wang X, Hoshiyama M, Kakigi R. A comparative magnetoencephalographic study of cortical activations evoked by noxious and innocuous somatosensory stimulations. *Neuroscience* 2003;120:235–48.
- Jasmin L, Granato A, Ohara PT. Rostral agranular insular cortex and pain areas of the central nervous system: a tract-tracing study in the rat. *J Comp Neurol* 2004;468:425–40.
- Jones EG. Thalamic circuitry and thalamocortical synchrony. *Philos Trans R Soc Lond B Biol Sci* 2002;357:1659–73.
- Jones EG, Powell TPS. Connexions of the somatic sensory cortex of the rhesus monkey. III. Thalamic connexions. *Brain* 1970;93:37–56.
- Jones AK, Brown WD, Friston KJ, Qi LY, Frackowiak RS. Cortical and subcortical localization of response to pain in man using positron emission tomography. *Proc R Soc Lond B* 1991;244:39–44.
- Kasamatsu A, Hirai T. An electroencephalographic study on the zen meditation (Zazen). *Folia Psychiatr Neurol Jpn* 1966;20:315–36.
- Kasamatsu A, Okuma T, Takenaka S. The EEG of zen and yoga practitioners. *Electroencephalogr Clin Neurophysiol* 1957;9:51–2.
- Kakigi R, Koyama S, Hoshiyama M, Kitamura Y, Shimojo M, Watanabe S. Pain-related magnetic fields following CO₂ laser stimulation in man. *Neurosci Lett* 1995;192:45–8.
- Kanda M, Shindo K, Xu X, Fujiwara N, Ikeda A, Nagamine T, et al. Cortical mechanisms underlying point localization of pain spot as studied by event-related potentials following CO₂ laser stimulation in man. *Exp Brain Res* 1999;127:131–40.
- Kjaer TW, Bertelsen C, Piccini P, Brooks D, Alving J, Lou HC. Increased dopamine tone during meditation-induced change of consciousness. *Brain Res Cogn Brain Res* 2002;13:255–9.
- Lenz FA, Ohara S, Gracely RH, Dougherty PM, Patel SH. Pain encoding in the human forebrain: binary and analog exteroceptive channels. *J Neurosci* 2004;24:6540–4.
- Lou HC, Kjaer TW, Friberg L, Wildschiodt G, Holm S, Nowak M. A ¹⁵O-H₂O PET study of meditation and the resting state of normal consciousness. *Hum Brain Mapp* 1999;7:98–105.
- Mesulam MM, Mufson EJ. Insula of the old world monkey: III. Efferent cortical output and comments on function. *J Comp Neurol* 1982;212:38–52.
- Nakata H, Inui K, Wasaka T, Tamura Y, Tran DT, Qiu Y, et al. Movements modulate cortical activities evoked by noxious stimulation. *Pain* 2004;107:91–8.
- Nelson RJ, Kaas JH. Connections of the ventroposterior nucleus of the thalamus with the body surface representations in cortical areas 3b and 1 of the cynomolgus macaque (*Macaca fascicularis*). *J Comp Neurol* 1981;199:29–64.
- O'Connor DH, Fukui MM, Pinsk MA, Kastner S. Attention modulates responses in the human lateral geniculate nucleus. *Nat Neurosci* 2002;5:1203–9.
- Pandya DN, Van Hoesen GW, Mesulam M-M. Efferent connections of the cingulate gyrus in the rhesus monkey. *Exp Brain Res* 1981;42:319–30.
- Peyron R, Frot M, Schneider F, Garcia-Larrea L, Mertens P, Barral FG, et al. Role of operculoinsular cortices in human pain processing: covering evidence from PET, fMRI, dipole modeling, and intracerebral recordings of evoked potentials. *Neuroimage* 2002;17:1336–46.
- Ploner M, Schmitz F, Freund HJ, Schnitzler A. Parallel activation of primary and secondary somatosensory cortices in human pain processing. *J Neurophysiol* 1999;81:3100–4.
- Rainville P, Duncan GH, Price DD, Carrier B, Bushnell MC. Pain affect encoded in human anterior cingulate but not somatosensory cortex. *Science* 1997;277:968–71.
- Rainville P, Hofbauer RK, Paus T, Duncan GH, Bushnell MC, Price DD. Cerebral mechanisms of hypnotic induction and suggestion. *J Cogn Neurosci* 1999;11:110–25.
- Rainville P, Hofbauer RK, Bushnell MC, Duncan GH, Price DD. Hypnosis modulates activity in brain structures involved in the regulation of consciousness. *J Cogn Neurosci* 2002;14:887–901.
- Sawamoto N, Honda M, Okada T, Hanakawa T, Kanda M, Fukuyama H, et al. Expectation of pain enhances responses to nonpainful somatosensory stimulation in the anterior cingulate cortex and parietal operculum/posterior insula: an event-related functional magnetic resonance imaging study. *J Neurosci* 2000;20:7438–45.
- Svensson P, Minoshima S, Beydoun A, Morrow TJ, Casey KL. Cerebral processing of acute skin and muscle pain in humans. *J Neurophysiol* 1997;78:450–60.
- Talairach J, Tournoux P. Co-planar stereotaxic atlas of the human brain. New York, Thieme; 1988.
- Talbot JD, Marrett S, Evans AC, Meyer E, Bushnell MC, Duncan GH. Multiple representations of pain in human cerebral cortex. *Science* 1991;251:1355–9.
- Treede RD, Kenshalo DR, Gracely RH, Jones AK. The cortical representation of pain. *Pain* 1999;79:105–11.
- Treede RD, Apkarian AV, Bromm B, Greenspan JD, Lenz FA. Cortical representation of pain: functional characterization of nociceptive areas near the lateral sulcus. *Pain* 2000;87:113–9.

- Vogt BA, Pandya DN. Cortico-cortical connections of somatic sensory cortex (areas 3b, 1 and 2) in the rhesus monkey. *J Comp Neurol* 1978;177:179–92.
- Vogt BA, Pandya DN. Cingulate cortex of the rhesus monkey: II. Cortical afferents. *J Comp Neurol* 1987;262:271–89.
- Vogt BA, Pandya DN, Rosene DL. Cingulate cortex of the rhesus monkey: I. Cytoarchitecture and thalamic afferents. *J Comp Neurol* 1987;262:256–70.
- Watanabe S, Kakigi R, Koyama S, Hoshiyama M, Kaneoke Y. Pain processing by magnetoencephalography in the human brain. *Brain Topogr* 1998;10:255–64.
- Willis Jr WD, Zhang X, Honda CN, Giesler Jr GJ. A critical review of the role of the proposed VMpo nucleus in pain. *J Pain* 2002;3:79–94.
- Xu X, Fukuyama H, Yazawa S, Mima T, Hanakawa T, Magata Y, et al. Functional localization of pain perception in the human brain studied by PET. *Neuroreport* 1997;8:555–9.
- Yamasaki H, Kakigi R, Watanabe S, Naka D. Effects of distraction on pain perception: magneto- and electro-encephalographic studies. *Brain Res Cogn Brain Res* 1999;8:73–6.
- Yeterian EH, Pandya DN. Corticothalamic connections of paralimbic regions in the rhesus monkey. *J Comp Neurol* 1988;269:130–46.