

Clinical application of $^{62}\text{Zn}/^{62}\text{Cu}$ positron generator: Perfusion and plasma pool images in normal subjects

Hidehiko OKAZAWA,* Yasuhisa FUJIBAYASHI,** Yoshiharu YONEKURA,* Nagara TAMAKI,* Sadahiko NISHIZAWA,*
Yasuhiro MAGATA,* Koichi ISHIZU,* Tatsuhiro TSUCHIDA,* Norihiro SADATO,* Junji KONISHI,*
Akira YOKOYAMA,** Ren IWATA*** and Tatsuo IDO***

*Faculty of Medicine, **Faculty of Pharmaceutical Sciences, Kyoto University
***Cyclotron Radioisotope Center, Tohoku University

We have developed a new $^{62}\text{Zn}/^{62}\text{Cu}$ positron generator, and applied it for PET imaging of perfusion and plasma volume in 5 normal subjects. The generator makes it possible by a simple procedure to obtain ^{62}Cu eluate and labeling compounds sufficiently every 40–60 minutes. ^{62}Cu labeled pyruvaldehyde bis(N^4 -methylthiosemicarbazone) copper II (^{62}Cu -PTSM) was employed for cerebral and myocardial perfusion imaging and ^{62}Cu labeled human serum albumin-dithiosemicarbazone (^{62}Cu -HSA-DTS) was used for plasma pool imaging. The images of cerebral blood flow, cerebral plasma volume and myocardial perfusion were excellent. In addition, the analysis of tissue activity and blood activity demonstrated the microspheric character of ^{62}Cu -PTSM. Correction of arterial activity with the standard disappearance curve of ^{62}Cu -PTSM suggested the possibility of quantifying blood flow. The results of this study indicate the capability of the $^{62}\text{Zn}/^{62}\text{Cu}$ generator for wide clinical use without an in-house cyclotron.

Key words: ^{62}Cu -PTSM, ^{62}Cu -HSA-DTS, PET, perfusion tracer, plasma pool imaging

INTRODUCTION

THE $^{62}\text{Zn}/^{62}\text{Cu}$ POSITRON GENERATOR has been proposed as a possible source of generator-produced radiopharmaceuticals for positron emission tomography (PET), that has been expected to play an important role in wide clinical application of PET imaging without the use of an in-house cyclotron.¹ Although the physical half-life of the parent radionuclide is rather short (^{62}Zn ; 9 hr), a 10 min daughter half-life is thought to be suitable for PET imaging tracer. After copper (II) pyruvaldehyde bis(N^4 -methylthiosemicarbazone) labeled with ^{62}Cu (^{62}Cu -PTSM) had been applied as a perfusion tracer,^{2,3} excellent cerebral and myocardial perfusion images of human were obtained.⁴⁻⁷ Several quantitative approaches to the measurements of cerebral or myocardial blood flow with ^{62}Cu -PTSM have also been reported.⁵⁻¹⁰ As blood-pool imaging agents, ^{62}Cu labeled human serum albumin-dithiosemicarbazone (^{62}Cu -HSA-DTS)¹¹ and benzyl-

1,4,8,11-tetraazacyclotetradecan-N,N',N'',N'''-tetraacetic acid-albumin (^{62}Cu -benzyl-TETA-HSA)¹² were developed and investigated. These agents can provide cerebral and myocardial blood volume images and perfusion images on the same day.

For wide clinical application, this generator should possess a simple milking technique. The automated remote synthesis of ^{62}Cu -PTSM,¹³ and the new generator^{14,15} and labeling method by means of ligand exchange reaction^{11,16} can provide ^{62}Cu -PTSM and ^{62}Cu -HSA-DTS easily enough to use these tracers in clinical studies.

The present study shows the human application of the newly developed $^{62}\text{Zn}/^{62}\text{Cu}$ generator in normal volunteers. In order to evaluate the clinical applicability of this generator for perfusion and plasma volume imaging with PET, PET scans were performed with ^{62}Cu -PTSM and ^{62}Cu -HSA-DTS with blood sampling to examine the kinetics of these tracers.

MATERIALS AND METHODS

Preparation of $^{62}\text{Zn}/^{62}\text{Cu}$ generator, ^{62}Cu -PTSM, and ^{62}Cu -HSA-DTS

^{62}Zn was obtained by $^{63}\text{Cu}(p,2n)^{62}\text{Zn}$ nuclear reaction with

Received November 24, 1994, revision accepted January 23, 1995.

For reprint contact: Hidehiko Okazawa, M.D., Department of Nuclear Medicine, Kyoto University School of Medicine, 54, Shogoin Kawahara-cho, Sakyo-ku, Kyoto 606-01, JAPAN.

natural copper (^{63}Cu : 69.2%) as a target material. A $^{62}\text{Zn}/^{62}\text{Cu}$ generator was prepared with $^{62}\text{ZnCl}_2$ aqueous solution (1.1 GBq, pH 5.0) by the method reported previously.¹⁴ In this generator, cation-exchange resin (CG-120, Amberlite) was packed into a column and ^{62}Zn solution (1.1 GBq, in 2 ml water, pH 5.0) was loaded to adsorb ^{62}Zn . A glycine solution (200 mM) was used as the eluant and ^{62}Cu -glycine complex was obtained in the glycine solution. Elution efficiency was 60 to 70%, and the radiochemical purity was higher than 95%.

Pyruvaldehyde bis(N^4 -methylthiosemicarbazone) was prepared as described previously.¹⁷ The ^{62}Cu -PTSM was quantitatively obtained by simply mixing the generator eluate, ^{62}Cu -glycine and PTSM solution for a few seconds by a ligand exchange reaction.¹⁶ The product was acquired in a total volume of 4 ml ^{62}Cu -PTSM (0.1 mM PTSM in 5% DMSO) with glycine solution.

HSA-DTS was also synthesized by the method reported previously.¹¹ ^{62}Cu labeling of HSA-DTS was performed by simply mixing 4 ml of HSA-DTS solution (5 mg/ml in saline buffer (pH 6.0)) and 4 ml of ^{62}Cu -generator eluate.

Subjects

The study involved 5 male normal volunteers (age range, 30–46 years). Four subjects were investigated with both ^{62}Cu -PTSM and ^{62}Cu -HSA-DTS on separate days, and the other subject underwent only a ^{62}Cu -HSA-DTS study. The three subjects studied with ^{62}Cu -PTSM were scanned for imaging of both the brain and myocardium with a single dose of the tracer. The other subject was studied only for myocardial perfusion imaging. The study was approved by the Ethical Committee of Kyoto University Faculty of Medicine, and written informed consent was obtained from all the subjects before the PET study.

Positron emission tomography

The PCT-3600W (Hitachi Medical Co., Tokyo, Japan) was used as a PET imaging device.¹⁸ This system permits the simultaneous acquisition of 15 transverse slices with a center-to-center distance of 7 mm. All scans were performed at a resolution of 9 mm full width at half maximum (FWHM) in the transaxial direction and 6.5 mm in the axial direction. The field of view and pixel size of the reconstructed images were 256 mm and 2 mm for the brain, and 512 mm and 4 mm for the myocardium, respectively.

The subject's head was immobilized with a headholder. In the ^{62}Cu -PTSM study, a small cannula was placed in the left brachial artery for serial blood sampling in two subjects. In the study of ^{62}Cu -HSA-DTS, a small cannula was placed in the cubital vein contralateral to the administration side. Prior to all emission measurements, tomographic transmission data were obtained with a standard plate source of $^{68}\text{Ge}/^{68}\text{Ga}$ for attenuation correction. The tissue activity concentration in

the PET images was cross calibrated against the well counter with a cylindrical phantom filled with ^{18}F solution.

For perfusion imaging, 370–777 MBq (10–21 mCi) of ^{62}Cu -PTSM was injected intravenously over 5 seconds in a total volume of 4 ml. PET data acquisition of cerebral perfusion imaging was started at the time of ^{62}Cu -PTSM injection and continued for 10 minutes, in 15-second frames for the first 120 seconds and in 60-second frames for the next 8 minutes. In addition to the serial dynamic PET images, static images of 2 to 10 min after injection were reconstructed from dynamic scan data.

In the myocardial perfusion scanning, the data acquisition time course was in 10-second frames for the first 120 seconds, in 60-second frames for the next 6 minutes and finally in 240-second frames for the last 12 minutes (total 20 min). For the static images, dynamic scan data for 8 to 20 min after injection were used for reconstruction.

In order to obtain plasma volume imaging, 296–740 MBq (8–20 mCi) of ^{62}Cu -HSA-DTS was injected intravenously over 15 seconds in a total volume of 8 ml. PET data acquisition for the head was started 3 minutes after the administration of ^{62}Cu -HSA-DTS and continued for 16 minutes in 4-minute frames.

Tissue activity images of ^{62}Cu -PTSM reconstructed from the serial dynamic PET data and blood activity were corrected for physical decay of ^{62}Cu (half-life 9.74 min). In order to examine the kinetics of ^{62}Cu -PTSM, the regions of interest (ROIs) were placed on each serial dynamic PET image of the cerebrum and myocardium. For brain analysis, the ROI was placed to include the whole brain slice. For myocardial analysis, square ROIs were placed on the left ventricular (LV) wall and in the left atrium (LA) of the myocardium, 12×12 mm and 8×8 mm in size, respectively.

Measurement of blood radioactivity

In the ^{62}Cu -PTSM study, arterial blood samples were obtained manually from the left brachial artery in two scans of two subjects' myocardium, from the time of the intravenous injection to the end of the scan. One ml of blood was sampled every 10 seconds for the first 2 minutes and then every 60 seconds for the next 8 minutes, and then sampled at 15, 20 minutes after the injection. The blood samples thus obtained were immediately measured in a scintillation counter to obtain the arterial radioactivity. The arterial radioactivity was corrected by means of the standard curve for the percent octanol-extractable ^{62}Cu -PTSM obtained from 10 subjects reported previously.⁷

In the ^{62}Cu -HSA-DTS study, samples of 2 ml of venous blood were taken from the cubital vein beginning at 1 min after the administration of the tracer to the end of the scan with an interval of every 4 minutes. Each sample of

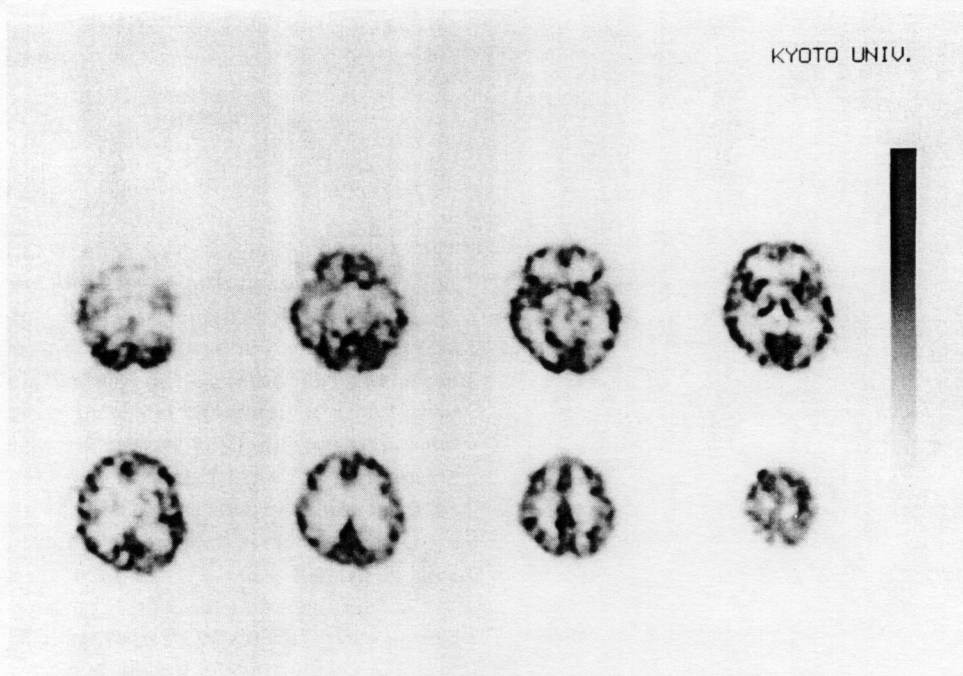


Fig. 1 PET images of transaxial slices of the human brain reconstructed from the dynamic PET data for 2 to 10 minutes after administration of ^{62}Cu -PTSM. Fairly high quality of CBF image was obtained with good contrast between gray and white matter.

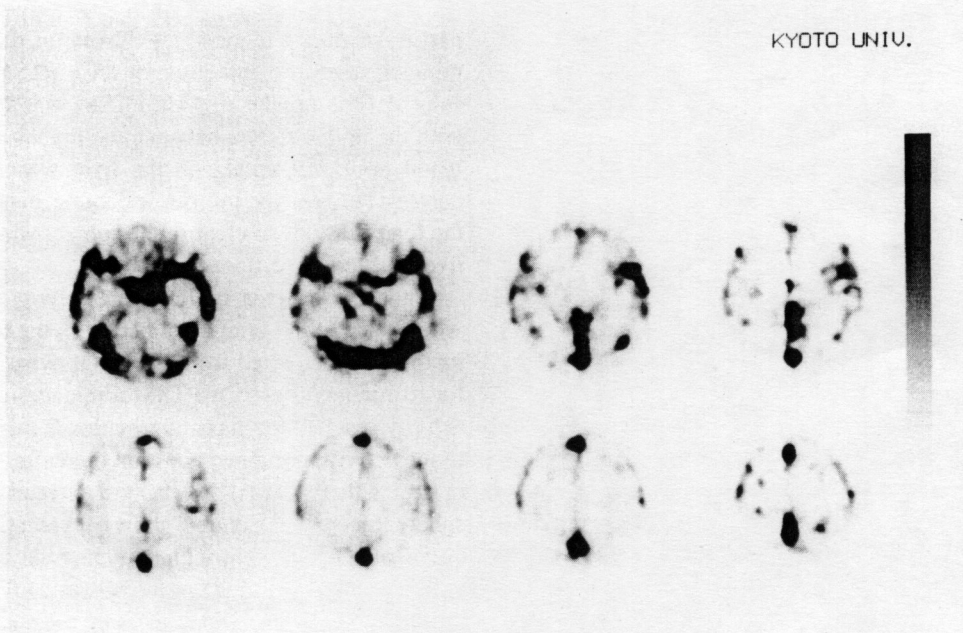


Fig. 2 Cerebral plasma volume images reconstructed from the dynamic PET data after administration of ^{62}Cu -HSA-DTS. The subject was same as Figure 1 and almost corresponding slice level is shown.

blood was divided into 0.5 ml and 1.5 ml and the latter samples were immediately centrifuged to measure plasma count.

RESULTS

Figure 1 shows the cerebral perfusion image reconstructed from the data for 2 to 10 minutes after the administration of ^{62}Cu -PTSM. A cerebral blood flow (CBF) image with

perfusion images reconstructed from the data for 8 to 20 minutes after the injection of $^{67}\text{Cu-PTSM}$ in another subject. The uptake of $^{67}\text{Cu-PTSM}$ was homogeneous with the high contrast between the myocardium and the blood pool, but uptake in the liver was high and the contrast between the inferior wall of the myocardium and the liver was not so clear in the subject whose heart and liver located close to each other.

Figure 4 shows a typical time-activity curve in the whole slice of the brain obtained from the tissue activity images reconstructed from the serial dynamic PET scan for 10 minutes after $^{67}\text{Cu-PTSM}$ administration. The brain activity reached its maximum within 2 minutes and the tissue activity remained constant thereafter, which demonstrates that $^{67}\text{Cu-PTSM}$ has the character of a micro-sphere tracer.^{2-10,19} Figure 5 shows a typical time-activity curve of the left ventricular myocardial wall and left atrium obtained from the serial dynamic PET scan for 20 minutes after $^{67}\text{Cu-PTSM}$ injection. The sharp peak of activity in ROI placed over the left ventricular myocardial wall observed within one minute was considered to be due to the spillover of the intravascular activity, and the tissue activity remained constant from 2.5 to 20 min, similar to the brain perfusion study. The arterial blood activity measured in the same study reached its peak value at same time as the activity in the left atrium, followed by rapid clearance, and was almost stable 3 minutes after the injection. The activity in the left atrium demonstrated slight underestimation of the peak activity

good contrast between gray and white matter was obtained. Figure 2 shows the cerebral plasma pool image obtained from the data for 3 to 19 minutes after the administration of $^{67}\text{Cu-HSA-DTS}$ in the same subject. From the analysis of venous blood sampling, greater than 95% of total blood activity was found to exist in the plasma pool.

Figure 3 shows the transaxial sections of myocardial

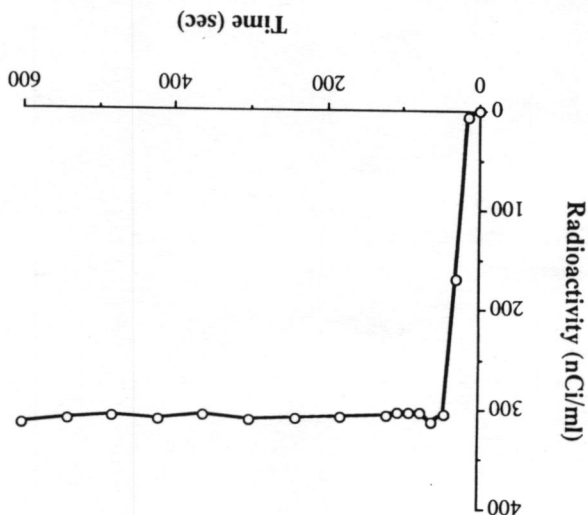
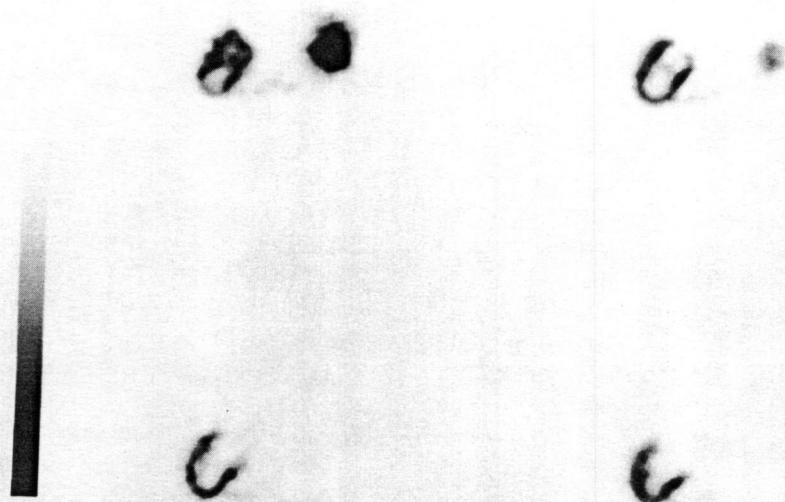


Fig. 4 Time-activity curve of whole brain obtained from serial dynamic PET scan after administration of $^{67}\text{Cu-PTSM}$. The maximal radioactivity was observed within 2 minutes, followed by the stable tissue activity for 10 min dynamic scan.

Fig. 3 Transaxial PET images of the human heart obtained from a normal subject after intravenous administration of $^{67}\text{Cu-PTSM}$. Eight to 20 minutes dynamic PET data were used for the reconstruction. Contrast between the myocardium and the blood pool is clear and relatively high quality images were also obtained. Note the high uptake in the liver.



and overestimation of the plateau value compared to the true arterial activity.

DISCUSSION

The $^{62}\text{Zn}/^{62}\text{Cu}$ positron generator and radiopharmaceuticals labeled with ^{62}Cu have been looked forward to by PET centers without an in-house cyclotron for wide clinical use. The aim of this study was to evaluate the clinical applicability of our new generator for PET imaging, and this generator was considered to be applicable to a wide clinical use because of the short interval required to obtain sufficient eluate and the simplicity of the labeling method. Subjects were able to undergo sequential scanning of brain perfusion and myocardial perfusion with one dose of ^{62}Cu -PTSM or studies before and after dipyridamole loading with an interval of one hour. These methods are available for clinical use when two or three scannings are needed in one patient on the same day.

The quality of images was excellent with good contrast between gray matter and white matter in the cerebrum, and between the myocardium and the blood pool in the heart. As reported previously on the retention mechanism of ^{62}Cu -PTSM, the first-pass extraction and back diffusion were completed within a few minutes,⁷ so that scanning between 2 and 10 minutes seemed to be the best timing in a cerebral ^{62}Cu -PTSM study. The quality of the brain image seemed to be better than with [$^{99\text{m}}\text{Tc}$]-d,l-hexamethylpropyleneamine oxime (HMPAO), but worse than ^{123}I -isopropyl iodoamphetamine (IMP) in comparison with SPECT tracers because of the extraction ratio.⁷ In the myocardial study with ^{62}Cu -PTSM, delayed data acquisition is considered to be better after sufficient clearance of blood activity to obtain better contrast images between the myocardium and the blood pool. Figure 5 shows that the radioactivity in the myocardial wall reached a plateau and the blood activity decreased to its minimum level about 3 minutes after the injection of ^{62}Cu -PTSM. This result shows that the most suitable length of time for myocardial perfusion image scanning is between 3 and 20 min. In this graph, slight underestimation of the peak activity, and overestimation of the plateau value in LA was observed compared to the true arterial activity. The difference between arterial sampling and dynamic PET data in the counting interval was considered to be one of the reasons for the underestimation of the peak count. The partial volume effect could be another reason for underestimation. Overestimation of the plateau value was considered to be due to the spillover from the myocardial wall.²⁰ The plasma pool image obtained with ^{62}Cu -HSA-DTS represented less noise than the CBV image obtained by the C^{15}O bolus inhalation method. The possible long scanning time is likely to be the reason for better image quality.

Quantitative approaches to measuring blood flow by means of ^{62}Cu -PTSM have already reported in several

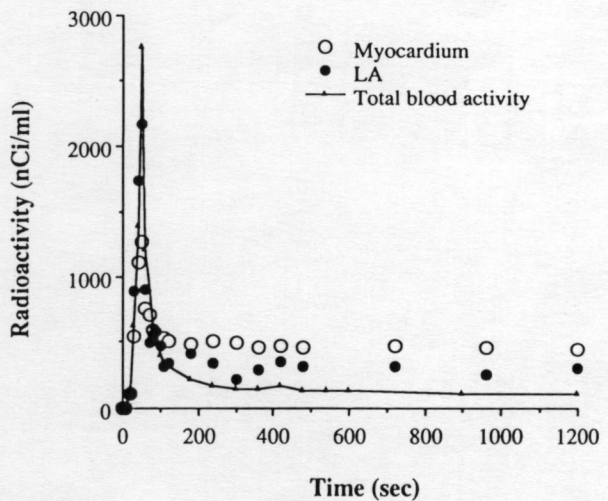


Fig. 5 Time-activity curves of the left ventricular wall and the left atrium (LA) obtained from serial dynamic PET scan after ^{62}Cu -PTSM injection. The sharp peak of the LV wall seen within one min was caused by the spillover due to the higher vascular radioactivity. The tissue activity remained constant between 2.5 and 20 min. The arterial blood activity measured in the same study (solid line) reached a peak value within 40 sec, followed by rapid clearance and almost stable 3 minutes after the injection. The activity in the LA demonstrated similar change to the arterial blood activity.

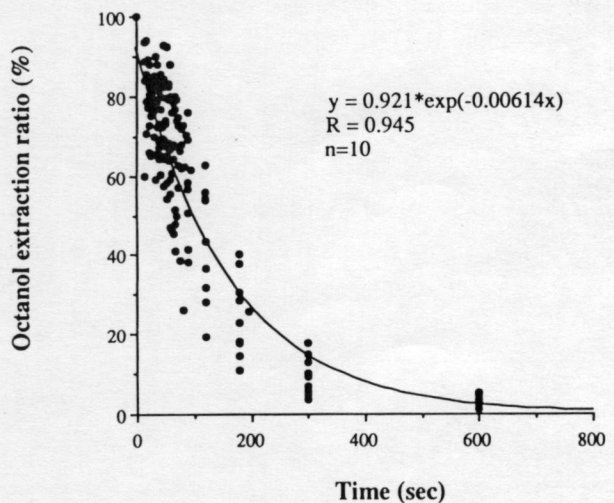


Fig. 6 The percentage of octanol-extractable ^{62}Cu -PTSM count in blood with respect to the total blood activity after the intravenous injection of ^{62}Cu -PTSM in 10 subjects. The rate of disappearance of ^{62}Cu -PTSM from blood was rapid and fitted monoexponentially.

articles.⁵⁻¹⁰ Although estimation of the accurate input function is essential for quantification of cerebral or myocardial blood flow, low level blood radioactivity remained constant beyond 3 minutes due to metabolites or other components. Herrero et al. estimated the true input function by using the standard curve of the octanol-extractable ^{62}Cu -PTSM ratio obtained from five dogs.⁶ They used this standard monoexponential curve for the

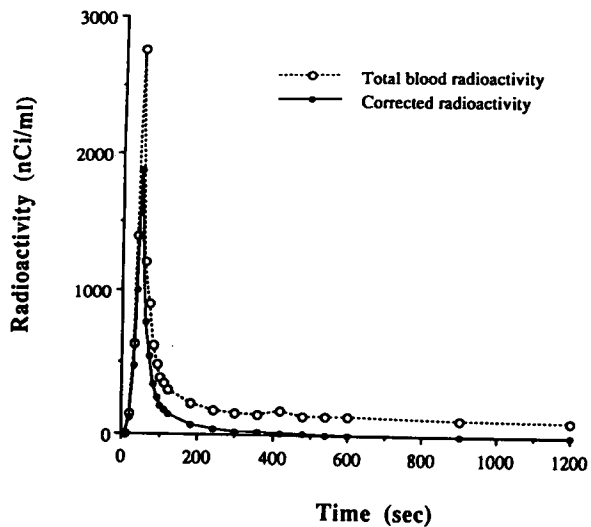


Fig. 7 Representative time-activity curves of the total blood (dashed line) and corrected radioactivity (solid line) of ^{62}Cu -PTSM obtained by sampling directly from the brachial artery. The arterial radioactivity showed rapid clearance, and the lipophilic activity was almost negligible about 3 min after the injection. The standard disappearance curve of ^{62}Cu -PTSM obtained from the octanol extraction study in 10 subjects was used for the correction of blood activity.

correction of sampled blood activity. If the activity in ROI placed on left atrium is corrected, the true input function can be estimated from the dynamic data noninvasively. Figure 6 shows the percentage of octanol-extractable ^{62}Cu -PTSM in blood with respect to total blood activity as a function of time after intravenous injection of ^{62}Cu -PTSM in 10 subjects in another study.⁷ The rate of disappearance of ^{62}Cu -PTSM from blood was rapid and it could also be fitted monoexponentially. Figure 7 shows the time-activity curves for ^{62}Cu -PTSM in the total arterial blood shown in Figure 5 (dashed line), and corrected radioactivity obtained with the monoexponential curve shown in Figure 6 (solid line). The estimated PTSM-associated radioactivity cleared more rapidly because of the swift conversion of ^{62}Cu -PTSM to the hydrophilic compounds. The corrected activity was almost negligible at 3 minutes after the injection despite remaining the total blood radioactivity thereafter, which was consistent with the results of our previous study.⁷ The estimated PTSM-associated radioactivity means the correction for the lipophilic part of blood activity that is considered to be the true input function.^{6,7} With this standard curve, arterial radioactivity can be corrected from the arterial sampling or dynamic data for the myocardial cavity to estimate the true input function, which indicates the possibility of quantitative analysis.

The results of this study demonstrate the suitability of the new $^{62}\text{Zn}/^{62}\text{Cu}$ generator for wide clinical use. ^{62}Cu -PTSM and ^{62}Cu -HSA-DTS can be provided at intervals of 40–60 minutes by a simple method. The quality of the perfusion images and blood pool images was excellent

and the possibility of quantification was indicated.

REFERENCES

1. Robinson GD, Zielinski FW, Lee AW. The zinc-62/copper-62 generator: a convenient source of copper-62 radiopharmaceuticals. *Int J Appl Radiat Isot* 31: 111–116, 1980.
2. Green MA. A positron copper radiopharmaceutical for imaging the heart and brain: copper-labeled pyruvaldehyde bis(N⁴-methylthiosemicarbazone). *Nucl Med Biol* 14: 59–61, 1987.
3. Green MA, Klippenstein DL, Tennison JR. Copper(II) bis(thiosemicarbazone) complexes as potential tracers for evaluation of cerebral and myocardial blood flow with PET. *J Nucl Med* 29: 1549–1557, 1988.
4. Green MA, Mathias CJ, Welch MJ, McGuire AH, Perry D, Rubio FF, et al. Copper-62-labeled pyruvaldehyde bis(N⁴-methylthiosemicarbazone)copper(II): synthesis and evaluation as a positron emission tomography tracer for cerebral and myocardial perfusion. *J Nucl Med* 31: 1989–1996, 1990.
5. Beanlands RSB, Muzik O, Mintun M, Mangner T, Lee K, Petry N, et al. The kinetics of copper-62-PTSM in the normal human heart. *J Nucl Med* 33: 684–690, 1992.
6. Herrero P, Markham J, Weinheimer CJ, Anderson CJ, Welch MJ, Green MA, et al. Quantification of regional myocardial perfusion with generator-produced ^{62}Cu -PTSM and positron emission tomography. *Circulation* 87: 173–183, 1993.
7. Okazawa H, Yonekura Y, Fujibayashi Y, Nishizawa S, Magata Y, Ishizu K, et al. Clinical application and quantitative evaluation of generator-produced ^{62}Cu -PTSM as a brain perfusion tracer for PET. *J Nucl Med* 35: 1910–1915, 1994.
8. Mathias CJ, Welch MJ, Raichle ME, Mintun MA, Lich LL, McGuire AH, et al. Evaluation of a potential generator-produced PET tracer for cerebral perfusion imaging: single-pass cerebral extraction measurements and imaging with radiolabeled Cu-PTSM. *J Nucl Med* 31: 351–359, 1990.
9. Shelton ME, Green MA, Mathias CJ, Welch MJ, Bergmann SR. Kinetics of copper-PTSM in isolated hearts: a novel tracer for measuring blood flow with positron emission tomography. *J Nucl Med* 30: 1843–1847, 1989.
10. Shelton ME, Green MA, Mathias CJ, Welch MJ, Bergmann SR. Assessment of regional myocardial and renal blood flow with copper-PTSM and positron emission tomography. *Circulation* 82: 990–997, 1990.
11. Fujibayashi Y, Matsumoto K, Arano Y, Yonekura Y, Konishi J, Yokoyama A. ^{62}Cu -labeling of human serum albumin-dithiosemicarbazone (HSA-DTS) conjugate for regional plasma volume measurement: application of new $^{62}\text{Zn}/^{62}\text{Cu}$ generator system. *Chem Pharm Bull* 38: 1946–1948, 1990.
12. Mathias CJ, Welch MJ, Green MA, Diril H, Meares CF, Gropler RJ, et al. *In vivo* comparison of copper blood-pool agents: potential radiopharmaceuticals for use with copper-62. *J Nucl Med* 32: 475–480, 1991.
13. Mathias CJ, Margenau WH, Brodsky JW, Welch MJ, Green MA. A remote system for the synthesis of copper-62 labeled Cu(PTSM). *Appl Radiat Isot* 42: 317–320, 1991.
14. Fujibayashi Y, Matsumoto K, Yonekura Y, Konishi J,

- Yokoyama Y. A new zinc-62/copper-62 generator as a copper-62 source for PET radiopharmaceuticals. *J Nucl Med* 30: 1838-1842, 1989.
15. Zweit J, Goodall R, Cox M, Babich JW, Potter GA, Sharma HL, et al. Development of a high performance zinc-62/copper-62 radionuclide generator for positron emission tomography. *Eur J Nucl Med* 19: 418-425, 1992.
 16. Matsumoto K, Fujibayashi Y, Yonekura Y, Wada K, Takemura Y, Konishi J, et al. Application of the new zinc-62/copper-62 generator: an effective labeling method for ^{62}Cu -PTSM. *Nucl Med Biol* 19: 39-44, 1992.
 17. Petering HG, Buskirk HH, Underwood GE. The antitumor activity of 2-keto-3-ethoxybutyraldehyde bis(thiosemicarbazone) and related compounds. *Cancer Res* 24: 367-372, 1964.
 18. Sadato N, Yonekura Y, Senda M, Iwasaki Y, Matoba N, Tamaki N, et al. PET and the autoradiographic method with continuous inhalation of oxygen-15-gas: theoretical analysis and comparison with conventional steady-state methods. *J Nucl Med* 34: 1672-1680, 1993.
 19. Minkel DT, Saryan LA, Petering DH. Structure-function correlations in the reaction of bis(thiosemicarbazone) copper(II) complexes with ehrlich ascites tumor cells. *Cancer Res* 38: 124-129, 1978.
 20. Takahashi N, Tamaki N, Kawamoto M, Magata Y, Okuda K, Nohara R, et al. Noninvasive and simple method for the estimation of myocardial metabolic rate of glucose by PET and ^{18}F -FDG. *KAKU IGAKU (Jpn J Nucl Med)* 31: 985-990, 1994.