

JNM



SPECT Images of Technetium-99m-Ethyl Cysteinate Dimer in Cerebrovascular Diseases: Comparison with Other Cerebral Perfusion Tracers and PET

Tatsuro Tsuchida, Sadahiko Nishizawa, Yoshiharu Yonekura,
Norihiro Sadato, Yasushi Iwasaki, Toru Fujita, Naoki Matoba,
Yasuhiro Magata, Nagara Tamaki and Junji Konishi

SPECT Images of Technetium-99m-Ethyl Cysteinate Dimer in Cerebrovascular Diseases: Comparison with Other Cerebral Perfusion Tracers and PET

Tatsuro Tsuchida, Sadahiko Nishizawa, Yoshiharu Yonekura, Norihiro Sadato, Yasushi Iwasaki, Toru Fujita, Naoki Matoba, Yasuhiro Magata, Nagara Tamaki and Junji Konishi

Departments of Nuclear Medicine and Brain Pathophysiology, Kyoto University Faculty of Medicine, Kyoto, Japan

To assess the clinical role of ^{99m}Tc -ethyl cysteinate dimer (ECD) as a cerebral perfusion tracer, 10 patients with unilateral cerebral infarction were studied. **Methods:** ECD SPECT images were compared with IMP and/or HMPAO SPECT in nine patients, seven in chronic phases and two in subacute phases. Five of these patients and one additional patient with chronic infarction received PET imaging in order to compare ECD distribution with quantitative regional cerebral blood flow (rCBF) and oxygen metabolism (rCMRO₂) images. **Results:** In patients with chronic cerebral infarction, regression analysis showed excellent correlation between ECD and IMP in the uptake ratio of lesions-to-nonaffected cortices ($r = 0.91$). In two cases of subacute infarction, decreased uptake of ECD was observed in the area of "luxury perfusion," which showed elevated or preserved rCBF with diminished rCMRO₂. On visual analysis, ECD image contrast was less prominent compared to that of IMP, but contrast was better than that of HMPAO. **Conclusions:** ECD uptake showed a curvilinear relationship against rCBF, suggesting flow-limited uptake in a high flow range. ECD is a clinically useful cerebral perfusion tracer with distinct characteristics when compared with other available agents.

Key Words: technetium-99m-ethyl cysteinate dimer; cerebrovascular disease

J Nucl Med 1994; 35:27-31

The introduction of single-photon emission computed tomography (SPECT) for brain perfusion imaging required the development of radiotracers which efficiently cross the blood-brain barrier (BBB) so that uptake is proportional to cerebral blood flow (1). In recent years, several cerebral perfusion tracers with different characteristics have been developed for SPECT imaging.

Iodine-123-N-isopropyl-p-iodoamphetamine (IMP) was

the first of these radiotracers to be applied successfully for SPECT imaging of the human brain. IMP crosses the BBB rapidly and remains in the brain for sufficient time for SPECT imaging, although tracer distribution in the brain changes gradually with time (2). Unlike ^{99m}Tc tracers, certain physical characteristics of ^{123}I , however, are not advantageous for its clinical use. Emission of its high-energy photons and a longer half-life restricts clinical dosage (1). Premedication is necessary for thyroid blocking. In addition, it is difficult to handle emergency situations for ^{123}I because a large cyclotron is needed for its production (3).

Technetium-99m-labeled d,l-hexamethyl-propyleneamine oxime (HMPAO) is the first commercially available ^{99m}Tc brain perfusion agent (4) and has wide clinical use. HMPAO, however, has limitations. A fresh, uncontaminated eluate of ^{99m}Tc is necessary for satisfactory labeling. Rapid decomposition of the labeled compound in vitro requires its use within 30 min of preparation (5). Significant backdiffusion of unmetabolized lipophilic HMPAO from the brain to the blood results in poor image contrast between the normal region and the hypoperfused area (6).

Technetium-99m-ethyl cysteinate dimer (ECD), a radiochemically stable brain perfusion agent (7,8), is a reportedly good marker for regional cerebral blood flow (rCBF) in strokes and other neurological diseases (1). In a study of intrasubject comparison between ECD and HMPAO with normal volunteers, ECD showed better brain-to-background contrast than HMPAO and was "easier to interpret" with less extracerebral activity as compared to HMPAO (4). However, information on direct comparison of these agents in the same patients with neurological diseases is limited.

The purpose of this study was to compare ECD with two other radiotracers, IMP and HMPAO, in the same subjects with unilateral cerebral infarction. Particular effort was made to compare ECD images with cerebral blood flow and oxygen metabolism measured by PET with the ^{15}O -gas inhalation method.

Received Mar. 9, 1993; revision accepted Sept. 27, 1993.

For correspondence or reprints contact: Sadahiko Nishizawa, MD, Department of Nuclear Medicine, Kyoto University Faculty of Medicine, 54 Kawaharacho, Shogoin, Sakyo-ku, Kyoto, 606-01, Japan.

TABLE 1
Study Results

Patient no.	Age	Sex	Diagnosis (period from onset)	Angiographic findings	PET/SPECT
1	33	M	Chronic infarction (6 mo)	Right ICA occlusion	IMP
2	57	M	Chronic infarction (2 mo)		IMP
3	61	F	Chronic infarction (1 yr)	Left CCA stenosis	IMP, HMPAO
4	50	M	Chronic infarction (>2 yr)		CBF
5	63	M	Chronic infarction (5 mo)	Left ICA occlusion	IMP, CBF
6	46	M	Chronic infarction (>2 yr)	Right MCA occlusion	IMP, CBF
7	55	F	Chronic infarction (>2 yr)	Left ICA occlusion	IMP, HMPAO, CBF
8	38	F	Chronic infarction (1 mo)		IMP
9	53	M	Subacute infarction (19 days)		IMP, CBF
10	45	M	Subacute infarction (16 days)		HMPAO, CBF

ICA = internal carotid artery, CCA = common carotid artery, MCA = middle cerebral artery.

MATERIALS AND METHODS

Subjects

Ten patients between the age of 33 and 63 yr (7 males and 3 females) with unilateral cerebral infarction were included in this study (Table 1). These subjects were selected from 32 patients with various neurological diseases who had ECD SPECT studies as a part of a clinical trial. Informed consent was obtained from each patient and the study was approved by the institutional review board of Kyoto University Hospital.

All patients had unilateral cerebral infarction: eight in the chronic phase and two in the subacute phase. The diagnosis of unilateral infarction was obtained by the clinical symptoms and the findings of computed tomography. Subsequent angiographic examination in five patients revealed unilateral occlusion or marked stenosis of the middle cerebral, internal carotid or common carotid arteries. The interval from the onset of stroke to the ECD SPECT study was 1 mo to more than 2 yr for patients in the chronic phase and 16 to 19 days for patients in the subacute phase. All patients underwent ECD SPECT imaging. For comparison, an IMP SPECT study was performed on six patients, HMPAO on one and both IMP and HMPAO on two patients. In order to evaluate the relationship between tissue activity distribution of ECD and quantitative rCBF and regional cerebral metabolic rate of oxygen (rCMRO₂), PET was performed on six patients, including two with subacute cerebral infarction. Interexamination intervals for patients in chronic and subacute phases were within 2 wk and 3 days, respectively.

SPECT Imaging

ECD was prepared from two commercially supplied vials, one containing a sterile and nonpyrogenic lyophilized mixture and the other a liquid phosphate buffer (Daiichi Radioisotope Lab, Tokyo and DuPont Japan Ltd., Tokyo, Japan). Three milliliters of normal saline was injected into the first vial to dissolve its contents. Technetium-99m generator eluant (30 mCi) was injected into the second vial and 1.0 ml of the contents of the first vial was then transferred into the second vial. The mixture was allowed to stand at room temperature for 30 min, after which an approximate 25-mCi dose of ECD was administered intravenously.

Technetium-99m HMPAO was prepared from a freeze-dried kit (Amersham Pharmaceutical Co., Tokyo, Japan) by the addition of 30 mCi of freshly eluted pertechnetate in 5 ml of saline solution just prior to intravenous injection (~25 mCi dose).

Iodine-123-IMP (0.45 mg of N-isopropyl-p-iodoamphetamine hydrochloride in 3 ml saline solution) was supplied commercially

(Nihon Medi-Physics, Nishinomiya, Japan). Patients received 3 mCi of IMP intravenously. To block the accumulation of free radioactive iodine in the thyroid, potassium iodide (30 mg/day) was given for 4 days starting on the day before the study.

A multidetector ring-type SPECT scanner, which provides three transaxial images with a slice interval of 30 mm (SET-030W, Shimadzu Co., Kyoto, Japan) was used for SPECT imaging. The spatial resolution was 12 mm FWHM in center of the field of view, and the axial resolution was 23.5 mm FWHM (9). Two SPECT scans were obtained to acquire six slices of SPECT images at 15-mm intervals. Data acquisition was started at 5, 10 and 30 min after the administration of IMP, HMPAO and ECD, respectively. Scan time was 15 min for IMP and was 10 min for both ECD and HMPAO. The patient's head was positioned by the technologist who used a three-points cross-shaped light beam on the patient's face to ensure uniform positioning for SPECT imaging on a different day.

PET Study

The PCT-3600W system (Hitachi Medical Co., Tokyo, Japan) was used to obtain PET images (10). This scanner simultaneously acquires 15 slices with an interslice distance of 7 mm. Scanning was performed at a resolution of 9 mm FWHM in the transaxial plane and 6.5 mm in the axial direction. Prior to all emission measurements, tomographic transmission data (⁶⁸Ge/⁶⁸Ga) were obtained for photon attenuation correction. Tissue activity concentration in the images was cross-calibrated against the well counter using a cylindrical phantom filled with ¹⁸F solution. The subject's head was immobilized with head holders and positioning was done using a three-points cross-shaped light beam. A small catheter was placed in the brachial artery for blood sampling. The subject wore a light, disposable plastic mask and nasal cannula for inhalation of ¹⁵O gas produced by a small cyclotron (CYPRIS 325, Sumitomo Heavy Industries, Ltd., Tokyo, Japan). The steady-state inhalation method for ¹⁵O-labeled CO₂ and O₂ gases (300–500 MBq/min) with 5-min data acquisition and intermittent arterial blood sampling was used to calculate rCBF and rCMRO₂ (11).

Data Analysis

SPECT images were analyzed both visually and quantitatively. For visual analysis, two radiologists familiar with neuro-SPECT imaging (S.N. and Y.Y.) ranked SPECT image quality in four categories (excellent, good, fair and poor) and evaluated ECD image contrast in comparison with IMP and/or HMPAO. For quantitative analysis, eighteen pairs of 17-mm² regions of interest (ROIs) were placed on both sides of the cerebral cortices, white matter, basal

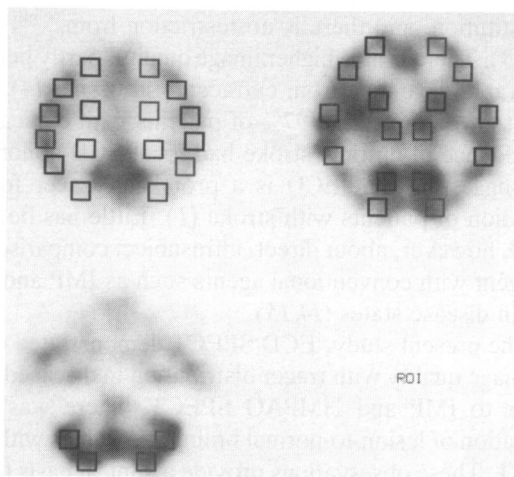


FIGURE 1. Regions of interest used in this study.

ganglia, thalami and cerebellar hemispheres of the identical slices on three levels among the SPECT and PET images (Fig. 1). First, image contrast of lesions to contralateral nonaffected areas (lesion-to-normal ratio) was compared between ECD and IMP SPECT images. In this analysis, hypoperfused lesions are defined on the IMP images as areas with IMP uptake less than 85% of the contralateral identical ROI. Second, relative ECD uptake in each region normalized by cerebellar uptake is plotted against relative rCBF also normalized by cerebellar CBF. In this analysis, the ROIs of the cerebellum ipsilateral to the cerebral lesion were used for normalization in order to eliminate the effect of crossed cerebellar diaschisis (6,12). Areas of "luxury perfusion" observed in two patients with subacute cerebral infarction were excluded from the quantitative analysis.

RESULTS

ECD SPECT images were equal to or better than IMP and HMPAO SPECT images in terms of image quality, whereas image contrast of ECD SPECT was less apparent when compared with IMP SPECT and slightly better than HMPAO SPECT (Table 2). Forty-one hypoperfused le-

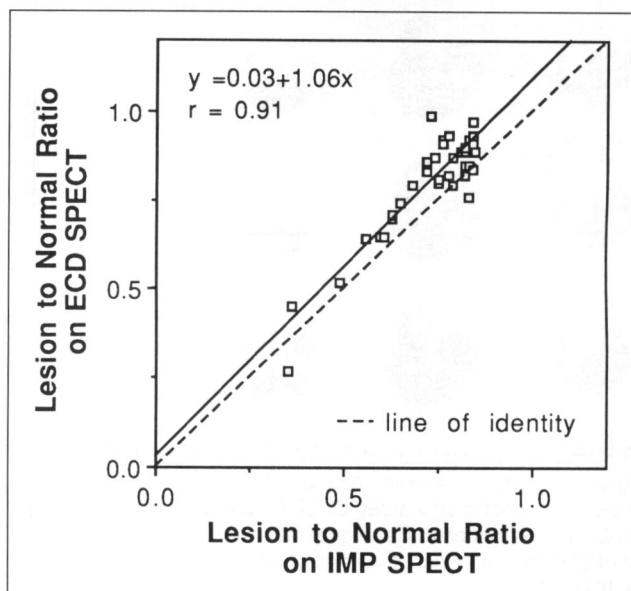


FIGURE 2. Comparison of ECD and IMP in lesion-to-normal ratios. A correlation was observed between ECD IMP and IMP SPECT. The regression line (solid line) is above the line of identity (dotted line), suggesting lesser image contrast with ECD than IMP.

sions were defined in seven patients who showed chronic cerebral infarction and received both ECD and IMP SPECT studies. Excellent correlation was found in the lesion-to-normal ratio between ECD and IMP SPECT ($r = 0.91$), although the ratios showed slightly less image contrast in ECD than IMP SPECT (Fig. 2). Figure 3 demonstrates typical of ECD, IMP and HMPAO SPECT images obtained from a patient with chronic cerebral infarction.

Plots of relative ECD uptake in each region normalized by cerebellar uptake against relative rCBF revealed a curvilinear relationship, indicating relatively less uptake of ECD compared with rCBF as rCBF increases (Fig. 4).

In two patients with subacute cerebral infarction, de-

TABLE 2
Visual Evaluation of SPECT Images

Patient no.	Image quality			Image contrast
	ECD	IMP	HMPAO	
1	Good	Fair	—	ECD > IMP*
2	Good	Fair	—	ECD = IMP
3	Good	Excellent	Good	IMP > ECD > HMPAO
4	Good	—	—	
5	Excellent	Good	—	IMP > ECD
6	Good	Good	—	IMP > ECD
7	Excellent	Good	Good	IMP > ECD > HMPAO
8	Good	Good	—	IMP > ECD
9	Good	Fair	—	ECD: cold [†] IMP: hot
10	Excellent	—	Good	ECD: cold HMPAO: iso

*Image contrast was evaluated visually in chronic infarction. A > B: better contrast in A than B.

[†]Uptake in the infarcted lesion was compared with that in normal cortex. cold = decreased uptake, hot = increased uptake, iso = same uptake as normal area.

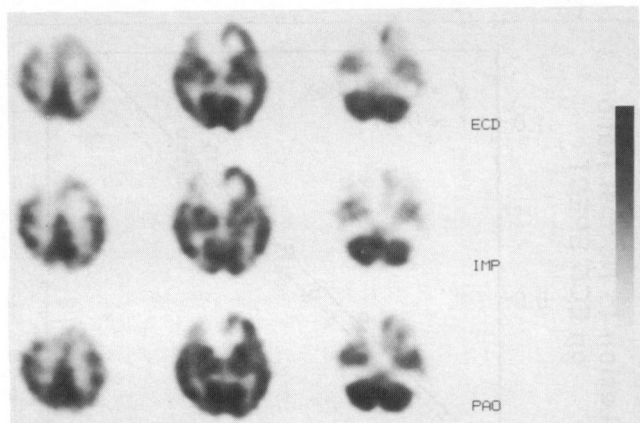


FIGURE 3. Comparison of SPECT ECD, IMP and HMPAO images in a case of chronic cerebral infarction (Patient 7). Similar images were obtained in three SPECT studies. The image contrast (lesion-to-normal contrast and gray matter-to-white matter contrast) of ECD is less prominent than that of IMP, but is better than that of HMPAO.

creased tracer uptake was observed in the infarcted area on ECD SPECT image, whereas IMP or HMPAO SPECT images showed increased or preserved uptake in the lesion (Table 2). In these cases, $rCMRO_2$ images showed decreased oxygen metabolism in the lesion, whereas blood flow to the lesion was relatively preserved, suggesting "luxury perfusion" in the infarcted lesion. Figure 5 shows SPECT images of ECD and HMPAO and PET images of $rCBF$ and $rCMRO_2$ in one of these cases (Patient 10).

DISCUSSION

ECD has several advantages over HMPAO as a brain perfusion agent. ECD is more stable for many hours after

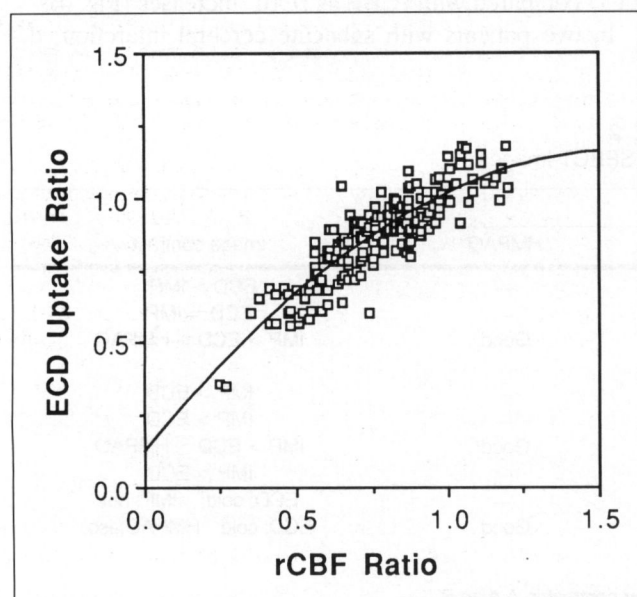


FIGURE 4. Comparison of ECD uptake ratio and $rCBF$ ratio shows curvilinear relationship.

reconstitution, and there is no restriction from ^{99m}Tc elution (13). There is also higher image quality, partly because of its rapid clearance from extracerebral tissues (4). Holman et al. reported that 97% of patients with clinical and CT evidence of chronic stroke had focal ECD abnormalities, suggesting that ECD is a promising tracer for the evaluation of patients with stroke (1). Little has been reported, however, about direct, intrasubject comparisons of this agent with conventional agents such as IMP and HMPAO in disease states (14,15).

In the present study, ECD SPECT demonstrated excellent image quality with tracer distribution in diseased brain similar to IMP and HMPAO SPECT. There was good correlation of lesion-to-normal brain ratio values with IMP SPECT. These observations provide a clinical basis for the use of ECD in cerebrovascular diseases. Image contrast of ECD SPECT is slightly worse than that of IMP SPECT, although better than that of HMPAO. This observation is explained by the different characteristics of these tracers. IMP has high first-pass extraction and small backdiffusion, resulting in a linear relationship between tissue activity and $rCBF$ up to the high flow range (16-18). In contrast, ECD showed a nonlinear relationship between tissue activity and $rCBF$ in the higher flow range as presented in this study. This nonlinear relationship of the flow tracer can be explained by limited first-pass extraction, backdiffusion of the tracer or both. ECD was reported to have a lower extraction fraction below 70% (13) and to have backdiffusion of the unmetabolized tracer from brain to blood in the initial phase after intravenous injection (19). These factors may result in less image contrast between high and low flow regions by ECD than by IMP.

On the other hand, because of relatively large backdiffusion in the early phase, HMPAO is known to underestimate cerebral blood flow in the high flow range (20), resulting in lower lesion-to-normal brain ratios. Backdiffusion of ECD is small compared to that of HMPAO (19), which may explain better lesion-to-normal ratios with ECD versus HMPAO.

In subacute cerebral infarction, a different distribution pattern was seen with ECD, IMP or HMPAO. ECD uptake in the lesion was very low in spite of preserved $rCBF$ and decreased $rCMRO_2$ proven by PET. This pattern was consistent with "luxury perfusion," where mismatch between blood flow and oxygen metabolism occurs.

The retention mechanism of ECD in the normal brain is thought to be due to the metabolism of the lipophilic complex to polar acid products that are trapped in the brain (21). Since this metabolic process is rapid, regional distribution of the compound in the brain appeared to be related to cerebral blood flow over a wide range (21). The mechanisms of reduced uptake of ECD in stroke may be the result of a variety of causes, including decreased blood flow, decreased tracer extraction or decreased metabolism due to the lack of oxygen and enzyme activity, which leads to enhanced tracer washout (1). Walovitch et al. predicted that metabolism of ECD in the brain might be decreased

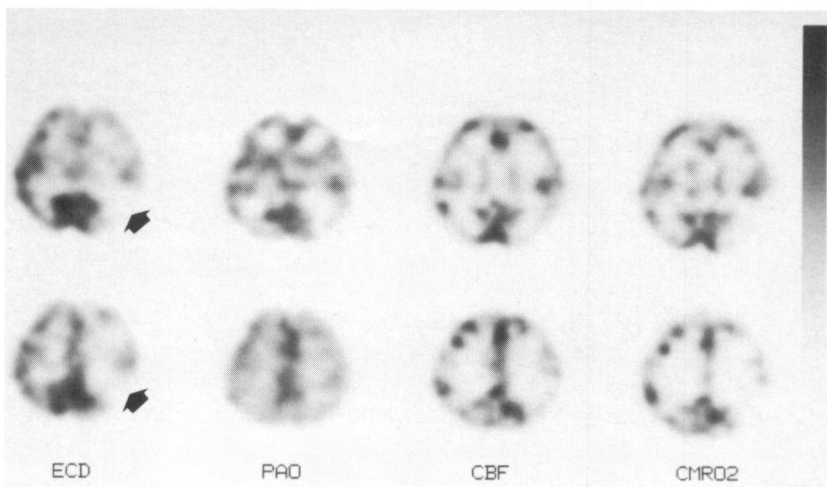


FIGURE 5. Comparison of ECD and HMPAO SPECT images with PET images in a case of subacute infarction (Patient 10). ECD SPECT showed decreased uptake in the left parieto-occipital region, whereas uptake was preserved on HMPAO SPECT. PET demonstrated decreased rCMRO₂ with preserved rCBF in the lesion.

sufficiently so that “membrane trapping” distribution becomes rate-limited and not equivalent to initial blood flow distribution (21).

Luxury perfusion is defined as the state of excess perfusion relative to reduced oxygen consumption of brain tissue. This is usually observed in subacute infarction (22). Since this situation might imply general reduction of enzymatic activity, ECD might be useful to assess brain tissue viability (1,23). This characteristic of ECD may also be advantageous in depicting tissue damage more directly than HMPAO. HMPAO is a marker of regional cerebral perfusion in stroke and will show transient hyperemia observed in some cases of subacute stroke (4). Uncoupling of flow and “membrane trapping” distribution should be considered to correctly interpret ECD SPECT images.

In conclusion, ECD is a clinically useful tracer of cerebral perfusion for the diagnosis of infarction. A different distribution pattern with this agent is seen when compared with conventional flow tracers in subacute infarction.

ACKNOWLEDGMENTS

The authors thank Hidenao Fukuyama, MD, Department of Neurology, and Masatsune Ishikawa, MD, Department of Neurosurgery, for their cooperation throughout the study.

REFERENCES

- Holman BL, Hellman RS, Goldsmith SJ, et al. Biodistribution, dosimetry and clinical evaluation of technetium-99m-ethyl cysteinate dimer in normal subjects and in patients with chronic cerebral infarction. *J Nucl Med* 1989; 30:1018-1024.
- Holman BL, Lee RGL, Hill TC, et al. A comparison of two cerebral perfusion tracers N-isopropyl-I-123-p-iodoamphetamine and I-123-HIPDM in the human. *J Nucl Med* 1984;25:25-30.
- Leveille J, Demonceau G, Roo MD, et al. Characterization of technetium-99m-L,L-ECD for brain perfusion imaging: part 2: biodistribution and brain imaging in humans. *J Nucl Med* 1989;30:1902-1910.
- Leveille J, Demonceau G, Walovitch RC. Intersubject comparison between technetium-99m-ECD and technetium-99m-HMPAO in healthy human subjects. *J Nucl Med* 1992;33:480-484.
- Neirinckx R, Canning L, Piper I, et al. Technetium-99m d,l-HM-PAO: a new radiopharmaceutical for SPECT imaging of regional cerebral blood perfusion. *J Nucl Med* 1987;28:191-202.
- Yonekura Y, Nishizawa S, Mukai T, et al. SPECT with ^{99m}Tc-d,l-hexamethyl-propylene amine oxime (HMPAO) compared with regional cerebral blood flow measured by PET: effects of linealization. *J Cereb Blood Flow Metab* 1988;8:S82-S89.
- Vallabhajosula S, Zimmerman RE, Picard M, et al. Technetium-99m ECD: a new brain imaging agent: in vivo kinetics and biodistribution studies in normal human subjects. *J Nucl Med* 1989;30:599-604.
- Orlandi C, Crane PD, Platts SH, et al. Regional cerebral blood flow and distribution of [^{99m}Tc]ethyl cysteinate dimer in nonhuman primates. *Stroke* 1990;21:1059-1063.
- Yonekura Y, Fujita T, Nishizawa S, et al. Multidetector SPECT scanner for brain and body: system performance and applications. *J Comput Assist Tomogr* 1989;13:732-740.
- Mukai T, Senda M, Yonekura Y, et al. System, design, and performance of a newly developed high-resolution PET scanner using double wobbling mode [Abstract]. *J Nucl Med* 1988;29(suppl):877.
- Frackowiak RS, Lenzi GL, Jones T, et al. Quantitative measurement of regional cerebral blood flow and oxygen metabolism in man using ¹⁵O and positron emission tomography: theory, procedure, and normal values. *J Comput Assist Tomogr* 1980;4:727-736.
- Yamauchi H, Fukuyama H, Yamaguchi S, et al. Crossed cerebellar hypoperfusion in unilateral major cerebral artery occlusive disorders. *J Nucl Med* 1992;33:1632-1636.
- Walovitch RC, Hill TC, Garrity ST, et al. Characterization of technetium-99m-L,L-ECD for brain perfusion imaging: part 1: pharmacology of technetium-99m-ECD in nonhuman primates. *J Nucl Med* 1989;30:1892-1901.
- Matsuda H, Kinuya K, Higashi S, et al. Evaluation of brain perfusion SPECT imaging using ^{99m}Tc-ECD. *Jpn J Nucl Med* 1991;28:701-709.
- Ono S, Yanagimoto S, Mimura H, et al. Usefulness of ^{99m}Tc-ECD SPECT in diseases of central nervous system: special reference to comparison to ¹²³I-IMP and ^{99m}Tc-HMPAO SPECT. *Jpn J Nucl Med* 1992;29:1429-1440.
- Kuhl DE, Barrio JR, Huang SC, et al. Quantifying local cerebral blood flow by N-isopropyl-p-[¹²³I]iodoamphetamine (IMP) tomography. *J Nucl Med* 1982;23:196-203.
- Winchell HS, Horst WD, Braun L, et al. N-isopropyl-[¹²³I] p-iodoamphetamine: single-pass brain uptake and washout, binding to brain synaptosomes and localization in dog and monkey brain. *J Nucl Med* 1980;21:940-946.
- Yonekura Y, Nishizawa S, Mukai T, et al. Functional mapping of flow and back-diffusion rate of N-isopropyl-p-iodoamphetamine in human brain. *J Nucl Med* 1993;34:839-844.
- Murase K, Tanada S, Inoue T, et al. Kinetic behavior of Tc-99m-ECD in the human brain using compartment analysis and dynamic SPECT: comparison with Tc-99m-HMPAO [Abstract]. *J Nucl Med* 1992;33(suppl):909.
- Andersen AR, Friberg HH, Schmidt JF, et al. Quantitative measurements of cerebral blood flow using SPECT and ^{99m}Tc-d,l-HM-PAO compared to xenon-133. *J Cereb Blood Flow Metab* 1988;8:S69-S81.
- Walovitch RC, Francheschi M, Picard M, et al. Metabolism of ^{99m}Tc-L,L-ethyl cysteinate dimer in healthy volunteers. *Neuropharmacology* 1991;30: 283-292.
- Moretti JL, Defer G, Cinotti L, et al. “Luxury perfusion” with ^{99m}Tc-HMPAO and ¹²³I-IMP SPECT imaging during the subacute phase of stroke. *Eur J Nucl Med* 1990;16:17-22.
- Shishido F, Uemura K, Murakami M, et al. Arterial clearance and cerebral uptake of Tc-99m-ECD in patients with cerebrovascular disease compared with PET. *Jpn J Nucl Med* 1992;29:27-34.