

Crossed Cerebellar Hypoperfusion in Unilateral Major Cerebral Artery Occlusive Disorders

Hiroshi Yamauchi, Hidenao Fukuyama, Shinya Yamaguchi, Toshiki Doi, Masafumi Ogawa, Yasuomi Ouchi, Jun Kimura, Norihiro Sadato, Yoshiharu Yonekura, Nagara Tamaki, and Junji Konishi

Department of Neurology, Department of Radiology and Nuclear Medicine, Faculty of Medicine, Kyoto University, Kyoto, Japan

We evaluated regional blood flow and oxygen metabolism in the cerebral and cerebellar cortices of 15 patients with unilateral major cerebral artery occlusive disorders with PET. These patients showed a cortical blood flow asymmetry in middle cerebral artery distribution. Only subcortical abnormalities were detected on computed tomography. Nine patients showed crossed cerebellar hypoperfusion, a reduction in contralateral cerebellar blood flow, while six did not. No difference in the degree of cerebral blood flow asymmetry existed between the two patient groups. However, oxygen metabolism asymmetry was more pronounced and was more closely matched to blood flow asymmetry in patients with crossed cerebellar hypoperfusion. These findings suggest that a major cause of cerebral cortical blood flow reduction is reduced metabolic demand in patients with crossed cerebellar hypoperfusion. Crossed cerebellar hypoperfusion may have clinical significance as a reflection of the cerebral metabolic state on blood flow images.

J Nucl Med 1992; 33:1632-1636

Crossed cerebellar diaschisis (CCD) was first demonstrated by Baron and coworkers with positron emission tomography (PET) in 1980 (1). In the clinical setting, single-photon emission computed tomography (SPECT) frequently documents CCD as crossed cerebellar hypoperfusion (CCH). However, the lack of established clinical expression makes the significance of CCH unclear.

To evaluate the risk for ischemia in patients with major cerebral artery occlusive disorders, it is essential to differentiate two conditions causing a decrease in cerebral blood flow (CBF) in the structurally normal brain tissue, namely reduced blood supply and reduced metabolic demand. Although measurement of both CBF and cerebral blood volume (CBV), sometimes in combination with oxygen extraction fraction (OEF), or paired CBF measurements before and after the application of some vasodilatory stimulus is possible (2), these are laborious. Barbiturate-in-

duced unilateral cortical neuronal depression (Wada test) causes CCH (3), but temporary carotid artery compression (Matas test) without transient neurological deficit does not (4), although both procedures produce CBF reduction in the distribution of the carotid artery. These findings support the hypothesis that CBF reductions caused by reduced metabolic demand are reflected as CBF decrement in the contralateral structurally normal cerebellum.

Our purpose was to evaluate the relationship between the cerebral cortical hemodynamic status and the presence of CCH in patients with unilateral major cerebral artery occlusive disorders, and to examine CCH as a reflection of the cerebral metabolic state.

PATIENTS AND METHODS

Patients

We studied a total of 15 patients with a unilateral major cerebral artery occlusive disorder, 13 with internal carotid artery (ICA) occlusion or stenosis and two with middle cerebral artery (MCA) occlusion. All subjects were retrospectively selected from a large series of patients in whom regional CBF, cerebral metabolic rate of oxygen (CMRO₂), OEF and CBV had been measured using PET. Criteria for selection were as follows: (1) an angiographically proven unilateral ICA or MCA occlusive disorder; (2) significant CBF asymmetry, which lay beyond the upper 95% confidence limits defined in eight normal subjects, as described below; (3) only subcortical abnormalities in the MCA territory of the hemisphere with the major cerebral artery disease on CT; (4) satisfactory visualization of the cerebellum on the PET images; (5) absence of clinical symptoms suggesting ischemic episodes in the vertebrobasilar artery territory; (6) absence of gross morphological alterations in the cerebellum and brainstem on computed tomography or magnetic resonance imaging; (7) normal angiographic findings in the vertebrobasilar system; and (8) PET study performed at least 1 mo after the latest stroke event.

There were 10 males and 5 females, aged 40-72 yr (mean \pm s.d. 60 \pm 8 yr), of which there were nine patients with ICA occlusions, four with ICA stenoses and two with MCA occlusions. Four patients had transient ischemic attacks and eleven had a minor completed stroke.

Positron Emission Tomographic Measurement

Specifications of our PET scanner have been reported elsewhere (5). In brief, the device has four rings, each containing 192 bismuth germinate detectors to provide seven tomographic slices at one scanning process. The device offers the best spatial reso-

Received Jan. 2, 1992; revision accepted Apr. 27, 1992.
For reprints contact: Dr. Hidenao Fukuyama, Department of Neurology, Faculty of Medicine, Kyoto University, 54 Shogoin Kawahara-cho, Sakyo-ku, Kyoto 606, Japan.

lution of 7.6 mm in FWHM at the center of the scan field and an axial resolution of 12 mm at the center. The scanning procedure was as follows. Before the study, a $^{68}\text{Ge}/^{68}\text{Ga}$ transmission scan was performed for 20 min for attenuation correction. Cerebral blood flow was determined while the subject continuously inhaled 370–555 MBq C^{15}O_2 per min through a mask. Measurement of CMRO_2 and OEF required continuous inhalation of 740 MBq to 1.11 GBq $^{15}\text{O}_2$ per min. Data were collected for 5 min. A single breath of 2.96 GBq C^{15}O was used to measure CBV. We calculated CBF, CMRO_2 , and OEF based on the steady-state method (6), and CMRO_2 and OEF were corrected by CBV (7). Functional images were reconstructed as constituting 64×64 pixels, each pixel representing 2.5×2.5 mm. When a Derenzo phantom was scanned, our PET scanner delineated hot spots of 2.5 mm diameter. The ratio of CBF-to-CBV was calculated pixel by pixel as an indicator of cerebral perfusion pressure (8).

Data Analysis

We analyzed four tomographic planes, 0.8, 4.0, 6.6 and 8.2 cm, above and parallel to the orbitomeatal line. These corresponded to the levels of the cerebellum, basal ganglia and thalamus, body of the lateral ventricle and centrum semiovale, respectively. For determination of the cerebellar regions of interest (ROIs), three circular ROIs, each containing 11 pixels (0.785 cm^2), were initially placed over the gray matter of the cerebellar hemisphere ipsilateral to the supratentorial lesion in the CBF image. We took care not to include the sinus in the ROIs by comparing this image with the CBV image. These ROIs were then copied over the contralateral side with respect to the antero-posterior axis. For determination of the cerebral ROIs, each of the three other images was examined by placing a total of 18 to 20 circular ROIs, each containing 11 pixels (0.785 cm^2), over the cortex. According to the atlas by Kretschmann and Weinrich (9), the ROIs in all three images were included in the distribution of the anterior cerebral artery (ACA), MCA and posterior cerebral artery (PCA), as well as the watershed areas between the ACA and MCA (anterior watershed, AWS) and the MCA and PCA (posterior watershed, PWS). A hemispheric value was calculated as the average of the MCA, AWS and PWS weighted by region size (10).

Patients with a significant CBF asymmetry were determined as follows: From the absolute CBF value, the percentage difference between ipsilateral (IL) and contralateral (CL) cerebral cortex to the major cerebral artery disease (cerebral $\Delta\%$) was calculated:

$$\text{Cerebral } \Delta\% = \frac{\text{CL} - \text{IL}}{\text{CL}} \times 100.$$

We also studied eight normal subjects (mean age 39 ± 14 yr), and the asymmetry index (AI) between the right (R) and left (L) cerebral cortex was calculated to obtain upper 95% confidence limits.

$$\text{Cerebral AI (absolute \% value)} = \frac{|R - L|}{R + L} \times 200,$$

where $|R - L|$ represents the absolute value of the difference. The cerebral AI in normal subjects was $2.33\% \pm 1.88\%$ (mean \pm s.d.). Fifteen patients with significant cerebral CBF asymmetry (i.e., an individual value of the cerebral $\Delta\%$ lying beyond 6.78% that covers the upper 95% limits defined in normal subjects) were selected.

These patients were divided into two groups according to the presence or absence of CCH, as described below. From the absolute CBF value, the percentage difference between the cerebellar cortex contralateral (CL) and ipsilateral (IL) to the major cerebral artery disease (cerebellar $\Delta\%$) was calculated:

$$\text{Cerebellar } \Delta\% = \frac{\text{IL} - \text{CL}}{\text{IL}} \times 100.$$

In the same eight normal subjects, the AI between the right (R) and left (L) cerebellar cortex was also calculated to obtain the upper 95% confidence limits.

$$\text{Cerebellar AI (absolute \% value)} = \frac{|R - L|}{R + L} \times 200.$$

The cerebellar AI in normal subjects was $2.29\% \pm 2.30\%$ (mean \pm s.d.). Nine patients had significant cerebellar CBF asymmetry (i.e., the individual value of the cerebellar $\Delta\%$ lying beyond 7.73% that covers the upper 95% limits defined in normal subjects) and consisted of four patients with ICA occlusions, three with ICA stenoses, and two with MCA occlusions (group CCH[+], mean \pm s.d. age 59 ± 9 yr). The other five patients with ICA occlusions and one with ICA stenosis exhibited no CCH (group CCH[-], mean \pm s.d. age 62 ± 4 yr). Clinical and neuroradiological data for the patients were summarized in Table 1.

The absolute hemispheric values, cerebral $\Delta\%$ in CBF and CMRO_2 , and the ratio of cerebral $\Delta\%$ in CMRO_2 to that in CBF from the patients with CCH were compared by Student's t-test with those from the patients without CCH. Differences giving $p < 0.05$ were considered significant.

RESULTS

The physiologic states of the two patient groups during PET scanning are described in Table 2, including PaCO_2 , PaO_2 , hematocrit, arterial hemoglobin concentration and mean arterial blood pressure.

Table 3 shows the mean hemispheric values for regional CBF, CMRO_2 , OEF, CBV and CBF/CBV for both cerebral hemispheres in the two patient groups. The patients without CCH had significantly decreased CBF and CBF/CBV, with significantly elevated OEF, in comparison to the patients exhibiting CCH in the hemisphere ipsilateral to major cerebral artery disease.

Figure 1 shows the relationship between the degree of CCH and CBF and CMRO_2 asymmetry, and the ratio of CMRO_2 asymmetry-to-CBF asymmetry. The degree of CBF asymmetry did not differ between the two groups (Fig. 1A). However, the degree of CMRO_2 asymmetry was significantly increased in patients with CCH ($p < 0.001$) and was significantly correlated with the degree of CCH in all patients (Fig. 1B). The degree of CMRO_2 -to-CBF asymmetry, indicating the extent of CMRO_2 reduction contributing to CBF reduction, was also significantly increased in patients with CCH ($p < 0.001$) (Fig. 1C). In other words, reduction in oxygen metabolism was more closely matched to CBF reduction in patients with CCH than in those without it.

TABLE 1
Patient Data

Patient No.	CCH	Age	Sex	Presentation	Angiography	Infarct on CT (Size, mm x mm)
1	(-)	65	M	Minor stroke	L ICAO	L Frontal subcortex (17 x 5)
2	(-)	63	M	Minor stroke	L ICAO	L Parietal subcortex (14 x 8)
3	(-)	70	M	TIA	R ICAS(95%)	None
4	(-)	64	M	Minor stroke	L ICAO	L Caudate head (7 x 3), L Corona radiata (8 x 8)
5	(-)	57	M	Minor stroke	L ICAO	L Parietal subcortex (10 x 10)
6	(-)	58	M	TIA	L ICAO	None
7	(+)	56	M	Minor stroke	R ICAO	R Caudate head (8 x 4), R Corona radiata (14 x 7)
8	(+)	69	F	Minor stroke	R MCAO	R Corona radiata (8 x 5)
9	(+)	40	F	Minor stroke	L ICAO	L Caudate head (7 x 4), L Corona radiata (5 x 3)
10	(+)	65	M	TIA	R ICAS(90%)	None
11	(+)	52	M	Minor stroke	R ICAO	R Frontal subcortex (12 x 6)
12	(+)	72	F	Minor stroke	R ICAS(95%)	R Parietal subcortex (12 x 10)
13	(+)	57	M	TIA	R ICAO	None
14	(+)	63	F	Minor stroke	L MCAO	L Putamen, L Internal capsule (anterior limb) (22 x 8)
15	(+)	63	F	Minor stroke	R ICAS(80%)	R Parietal subcortex (13 x 9)

TIA = transient ischemic attack; ICA = internal carotid artery; MCA = middle cerebral artery; O = occlusion; and S = stenosis.

DISCUSSION

In major cerebral artery occlusive disorders, patients having inadequate blood supply relative to metabolic demand might be at increased risk for cerebral ischemia (2), implying that identification of these patients is essential for the prevention of stroke. The detection of relative CBF reduction is feasible using SPECT. However, differentiation of reductions in CBF caused by reduced blood supply from those caused by reduced metabolic demand is laborious (2). In this study, we showed that the detection of CCH was useful for this differentiation. In patients with CCH, CMRO₂ asymmetry was more closely matched to CBF asymmetry than in those without it, indicating that reduced metabolic demand was a major cause of relative CBF reduction. Evaluation of absolute hemispheric values also disclosed that patients without CCH had less hemodynamic reserve (2,8), decreased CBF, increased OEF and decreased CBF/CBV in the affected cerebral cortex than

those with it. Although this method is only applicable to patients with CBF asymmetry, its simplicity of requiring only the evaluation of asymmetry on CBF images makes it practical. Naturally, our result requires confirmation as to whether it is true of individual patients examined prospectively, and what the sensitivity and specificity of the approach would be, because patient selection in this study was not prospective.

One PET study showed that CCD was not seen in two patients with decreased CMRO₂ and CBF in the distribution of an occluded carotid artery but without clinical or CT evidence for cerebral infarction, suggesting that actual irreversible tissue damage is necessary for the development

TABLE 2
Baseline Physiologic Data for Patients with and Without CCH

Parameter	CCH(+)	CCH(-)
PaCO ₂ (mmHg)	40.9 ± 3.4	40.4 ± 3.8
PaO ₂ (mmHg)	84.0 ± 8.8	82.5 ± 8.1
Ht (%)	37.5 ± 4.3	40.8 ± 4.1
Hb (g/dl)	12.8 ± 1.5	14.0 ± 1.3
MABP (mmHg)	100.2 ± 9.1	103.5 ± 11.6

Values are mean ± s.d.
MABP = mean arterial blood pressure.

TABLE 3
Values for regional CBF, CMRO₂, OEF, CBV and CBF-to-CBV Ratio in the Affected and Nonaffected Cerebral Hemispheres of Patients with and Without CCH

Variables	Hemisphere	CCH(-)	CCH(+)
CBF (ml/100 g/min)	Affected	28.30 ± 6.23*	36.17 ± 5.86
	Nonaffected	32.32 ± 6.82†	44.69 ± 5.49
CMRO ₂ (ml/100 g/min)	Affected	2.57 ± 0.29	2.56 ± 0.36
	Nonaffected	2.63 ± 0.25	3.04 ± 0.47
OEF (%)	Affected	51.65 ± 5.95*	45.47 ± 3.59
	Nonaffected	46.62 ± 7.62	42.80 ± 3.13
CBV (ml/100 g)	Affected	4.09 ± 0.66	3.95 ± 1.00
	Nonaffected	3.24 ± 0.50	3.84 ± 0.75
CBF/CBV (/min)	Affected	7.09 ± 1.76*	9.53 ± 2.08
	Nonaffected	10.17 ± 1.84	12.09 ± 2.57

* p < 0.05, † p < 0.01, differences between CCH(-) and CCH(+) (Student's t-test).

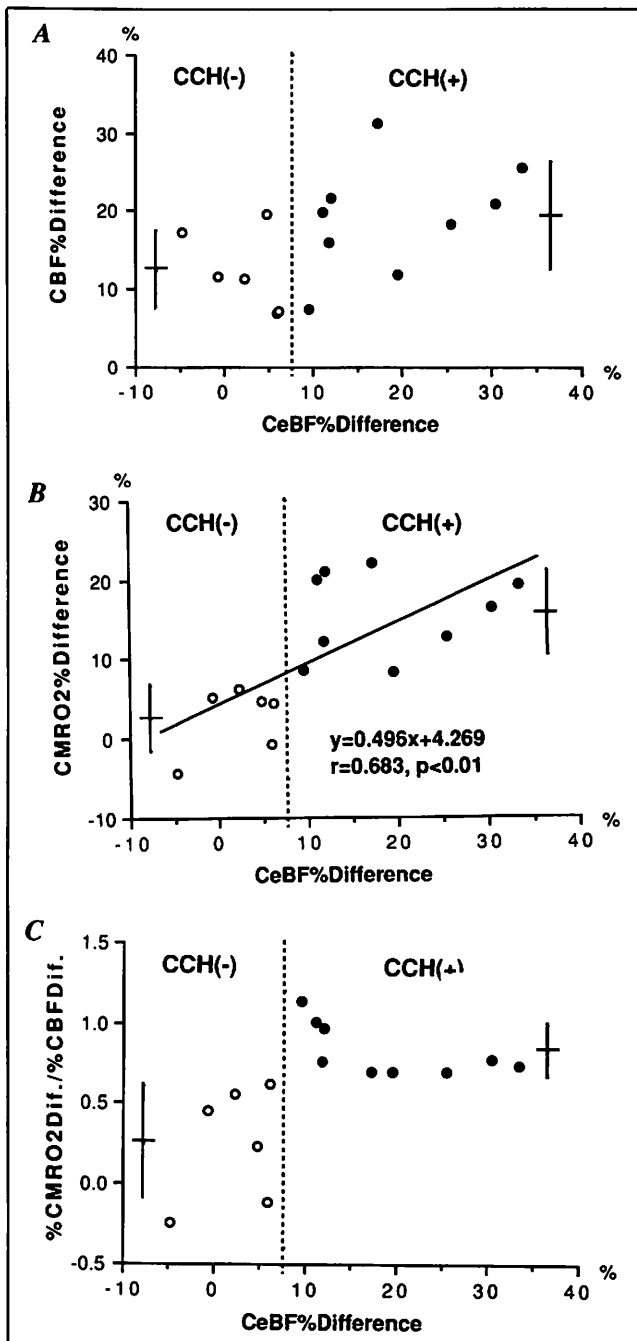


FIGURE 1. Scatter diagrams relate the degree of cerebellar blood flow asymmetry to cerebral asymmetry in CBF (A) and $CMRO_2$ (B) and the ratio of $CMRO_2$ asymmetry-to-CBF asymmetry (C). The dashed line shows the upper 95% limits of cerebellar CBF asymmetry defined in normal subjects. The solid bars indicate mean and standard deviation values in patients with CCH (right) and without CCH (left). CeBF: cerebellar blood flow.

of cerebellar diaschisis (11). However, a recent study demonstrated CCH in three patients with ICA occlusion, normal CT scans and cortical hypoperfusion (12). In addition, transient CCH has been reported in one patient with carotid transient ischemic attacks (13) and during barbiturate-induced unilateral cortical neuronal depression (Wada test) (3). These findings suggest that only hypo-

function of the cerebral cortex without morphological change is sufficient to produce CCH. In our patients without infarction, CCH would result from cerebral cortical hypometabolism due to hypofunction or neuronal cell loss without apparent tissue destruction.

In our patients with subcortical infarctions, in addition to primary ischemic cortical damage, secondary cerebral cortical hypometabolism due to a transneuronal mechanism and cerebro-cerebellar tract damage are responsible for CCH. Deep infarcts in the MCA territory, especially those destroying most of the internal capsule, were shown to most frequently and severely cause CCD (14). These infarcts, especially those disrupting the thalamo-cortical projections, also cause ipsilateral cerebral cortical hypometabolism, resulting in CCH (15). The degree of transneuronal metabolic depression, CCH or ipsilateral cerebral hypometabolism, depends on the location of the infarction. One study showed that an infarction limited to the posterior limb of the internal capsule caused CCH without hypometabolism in the ipsilateral cerebral cortex (16). This infarction results in CCH without regard to cerebral hemodynamic status in patients with major cerebral artery occlusive disorders. In our study, no patient had this infarction.

Besides the coexistence of a pure posterior capsular infarction, the relationship between the presence of CCH and the hemodynamics in the cerebral cortex described above disappeared in two cases that we excluded from this study. One case was a bilateral major cerebral artery occlusive disorder with CBF asymmetry. If cerebral hypometabolism resulting in CCH exists, the deleterious influence of bilateral occlusive disease on cerebral hemodynamics (17-19) produces more severe CBF reduction causing "misery perfusion" (20). The other was the bilateral cerebral metabolic depression due to transhemispheric diaschisis (21). In unilateral acute cerebral infarcts, the contralateral hemisphere showed depression of only $CMRO_2$ (22). Transhemispheric diaschisis might cause a more severe decrease in $CMRO_2$ than CBF, resulting in bilateral cerebral metabolic depression with asymmetry of CBF, which affects bilateral cerebellar metabolism. In this situation, cerebellar CBF asymmetry does not exist, despite a decrease in cerebral metabolism. The patients studied were selected while in the chronic stage, when transhemispheric diaschisis has disappeared (21,22).

CONCLUSION

Our results indicate that cerebral hemodynamic and metabolic status can be deduced from CBF change in the cerebellum in patients with unilateral major cerebral artery occlusive disorders, no cortical infarction and cortical CBF asymmetry. Only measurement of CBF by SPECT predicts whether or not cerebral metabolism is matched to CBF. Some exceptions can be checked by referring to clinical, angiographic, and computed tomographic findings. The relationship between cerebral hemodynamics and the pres-

ence of CCH should be studied in more patients using SPECT and vasodilative stimuli. Crossed cerebellar hypoperfusion will be a more useful finding with clinical significance.

ACKNOWLEDGMENTS

We thank Dr. H. Saji and Dr. Y. Magata for their support and advice.

REFERENCES

1. Baron JC, Bousser MG, Comar D, Castaigne P. "Crossed cerebellar diaschisis" in human supratentorial brain infarction. *Ann Neurol* 1980;8:128.
2. Powers WJ. Cerebral hemodynamics in ischemic cerebrovascular disease. *Ann Neurol* 1991;29:231-240.
3. Kurthen M, Reichmann K, Linke DB, et al. Crossed cerebellar diaschisis in intracarotid sodium amyloid procedures: a SPECT study. *Acta Neurol Scand* 1990;81:416-422.
4. Matsuda H, Higashi S, Asli IN, et al. Evaluation of cerebral collateral circulation by technetium-99m-HM-PAO brain SPECT during Matas test: report of three cases. *J Nucl Med* 1988;29:1724-1729.
5. Senda M, Tamaki N, Yonekura Y, et al. Performance characteristics of Positlogica III: a whole-body positron emission tomograph. *J Comput Assist Tomogr* 1985;9:940-946.
6. Frackowiak RSJ, Lenzi GL, Jones T, Heather JD. Quantitative measurement of regional cerebral blood flow and oxygen metabolism in man using ^{15}O and positron emission tomography: theory, procedure, and normal values. *J Comput Assist Tomogr* 1980;4:727-736.
7. Lammertsma AA, Jones T. Correction for the presence of intravascular oxygen-15 in the steady-state technique for measuring regional oxygen extraction ratio in the brain: 1. Description of the method. *J Cereb Blood Flow Metab* 1983;3:416-424.
8. Gibbs JM, Wise RJS, Leenders KL, Jones T. Evaluation of cerebral perfusion reserve in patients with carotid artery occlusion. *Lancet* 1984;1:310-314.
9. Kretschmann HJ, Weinrich W. Neuroanatomy and cranial computed tomography. *Grundlagen und klinische Anwendung*. New York: Thieme Inc.; 1986:70-74.
10. Yamauchi H, Fukuyama H, Yamaguchi S, Miyoshi T, Kimura J, Konishi J. High intensity area in the deep white matter indicating hemodynamic compromise in internal carotid artery occlusive disorders. *Arch Neurol* 1991;48:1067-1071.
11. Martin WRW, Raichle ME. Cerebellar blood flow and metabolism in cerebral hemisphere infarction. *Ann Neurol* 1983;14:168-176.
12. Pantano P, Lenzi GL, Guidetti B, et al. Crossed cerebellar diaschisis in patients with cerebral ischemia assessed by SPECT and 123I-HIPDM. *Eur Neurol* 1987;27:142-148.
13. Perani D, Gerundini P, Lenzi GL. Cerebral hemispheric and contralateral cerebellar hypoperfusion during a transient ischemic attack. *J Cereb Blood Flow Metab* 1987;7:507-509.
14. Pantano P, Baron JC, Samson Y, Bousser MG, Derouesne C, Comar D. Crossed cerebellar diaschisis. Further studies. *Brain* 1986;109:677-694.
15. Feeney DM, Baron JC. Diaschisis. *Stroke* 1986;17:817-830.
16. Pappata S, Mazoyer B, Dinh ST, Cambon H, Levasseur M, Baron JC. Effects of capsular or thalamic stroke on metabolism in the cortex and cerebellum: a positron tomography study. *Stroke* 1990;21:519-524.
17. Samson Y, Baron JC, Bousser MG, Loc'h C, Ottaviani M. Cerebral hemodynamic and metabolic changes in carotid artery occlusion: a PET study. In: Meyer JS, Lechner H, Reivich M, Ott EO, eds. *Cerebral vascular disease, volume 5*. Amsterdam: Excerpta Medica; 1985:128-135.
18. Leblanc R, Yamamoto YL, Tyler JL, Hakim A. Hemodynamic and metabolic effects on extracranial carotid disease. *Can J Neurol Sci* 1989;16:51-57.
19. Gibbs JM, Wise RJS, Leenders KL, Jones T. Evaluation of cerebral perfusion reserve in patients with carotid artery occlusion. *Lancet* 1984;1:310-314.
20. Baron JC, Bousser MG, Rey A, Guillard A, Comar D, Castaigne P. Reversal of focal "misery-perfusion syndrome" by extra-intracranial arterial bypass in hemodynamic cerebral ischemia. A case study with ^{15}O positron emission tomography. *Stroke* 1981;12:454-459.
21. Andrews RJ. Transhemispheric diaschisis. A review and comment. *Stroke* 1991;22:943-949.
22. Lenzi GL, Frackowiak RSJ, Jones T. Cerebral oxygen metabolism and blood flow in human cerebral ischemic infarction. *J Cereb Blood Flow Metab* 1982;2:321-335.

